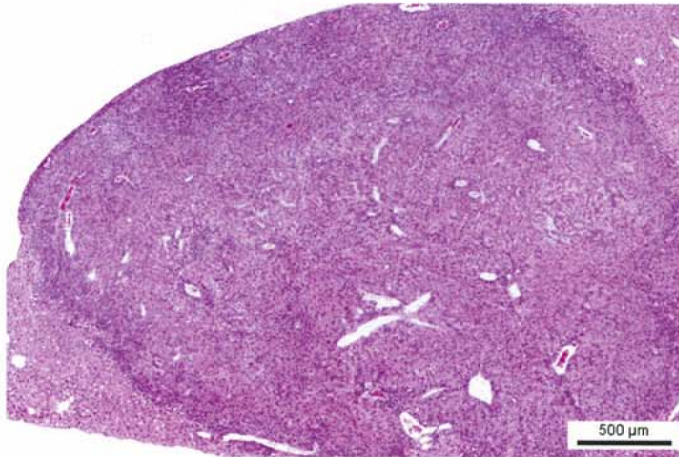


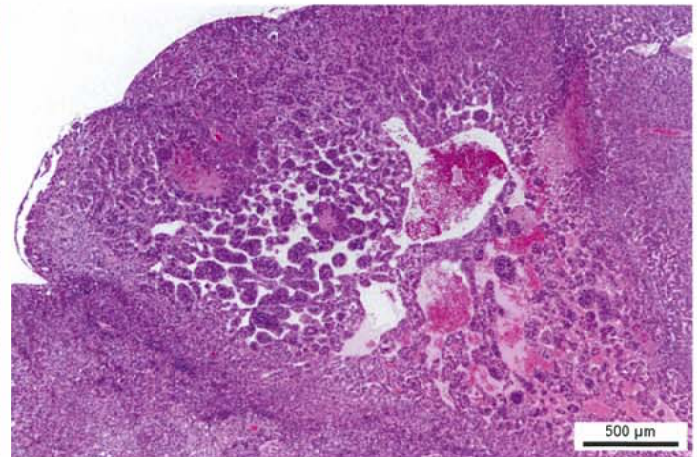
メタクリル酸ブチルのマウスを用いた吸入によるがん原性試験報告書

試験番号：0850

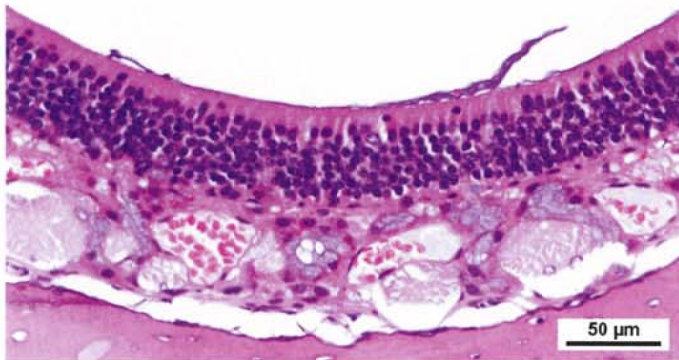
PHOTOGRAPHS



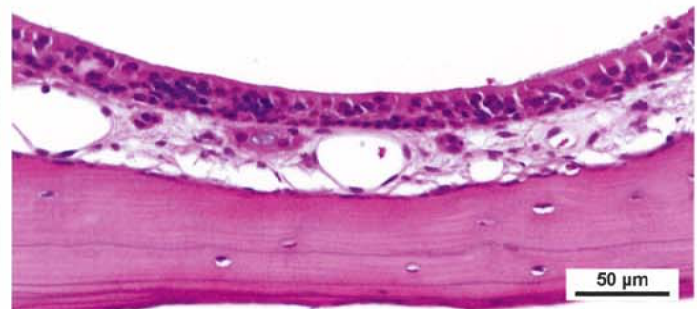
Photograph 1
Liver: Hepatocellular adenoma
Mouse, Male, 125 ppm, Animal No. 0850-1301 (H&E)



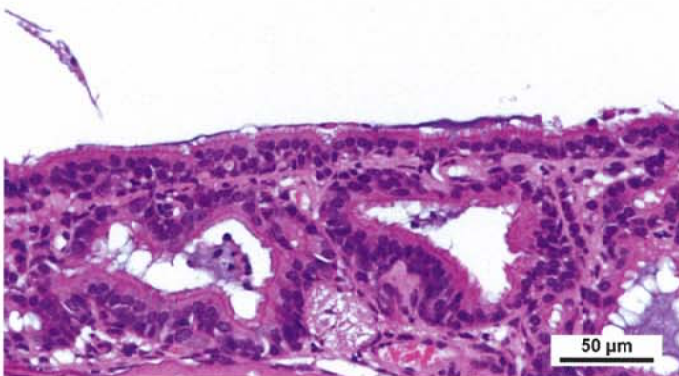
Photograph 2
Liver: Hepatocellular carcinoma
Mouse, Male, 125 ppm, Animal No. 0850-1347 (H&E)



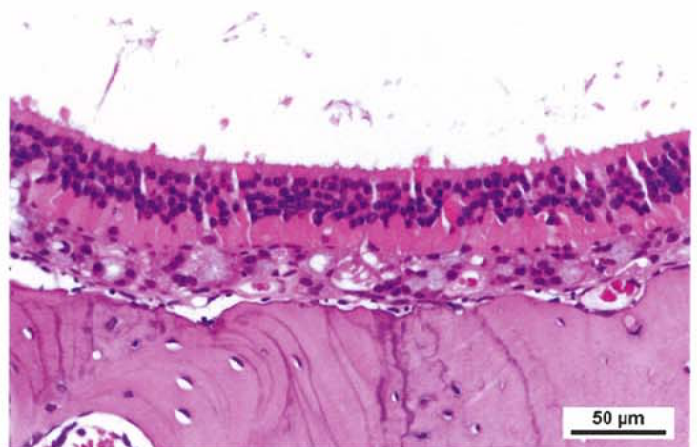
Photograph 3
Nasal cavity (olfactory epithelium): Normal
Mouse, Male, control, Animal No. 0850-1002 (H&E)



Photograph 4
Nasal cavity: Atrophy of olfactory epithelium
Mouse, Male, 125 ppm, Animal No. 0850-1305 (H&E)



Photograph 5
Nasal cavity: Respiratory metaplasia of olfactory epithelium
and gland of lamina propria
Mouse, Male, 125 ppm, Animal No. 0850-1329 (H&E)



Photograph 6
Nasal cavity: Eosinophilic change of olfactory epithelium
Mouse, Female, 125 ppm, Animal No. 0850-2312 (H&E)