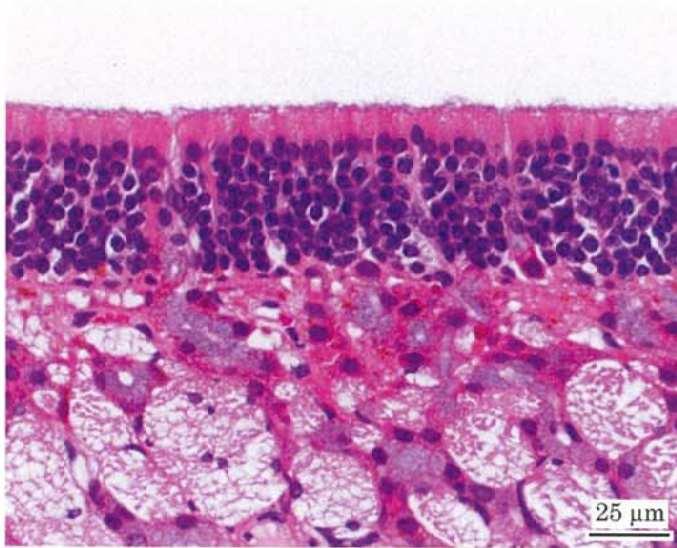


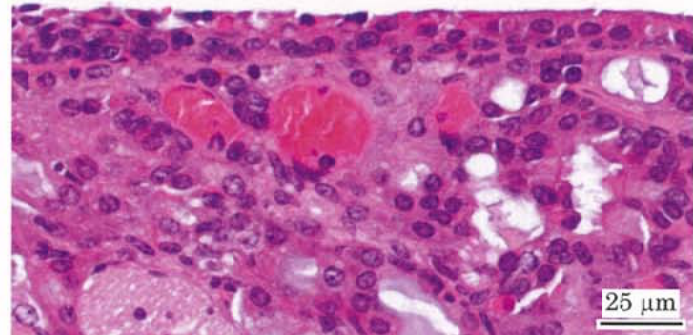
アクリル酸メチルのマウスを用いた吸入によるがん原性試験報告書

試験番号：0832

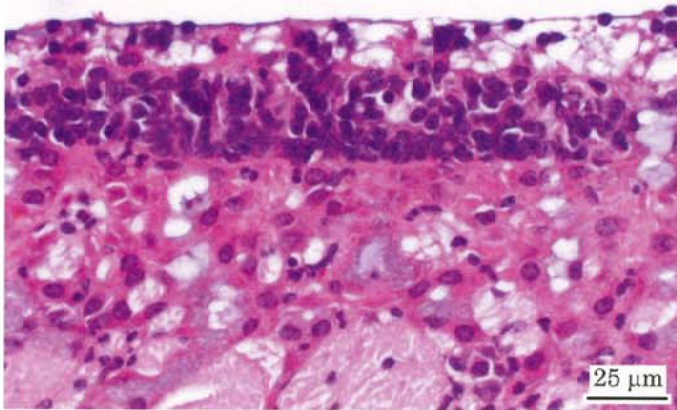
# PHOTOGRAPHS



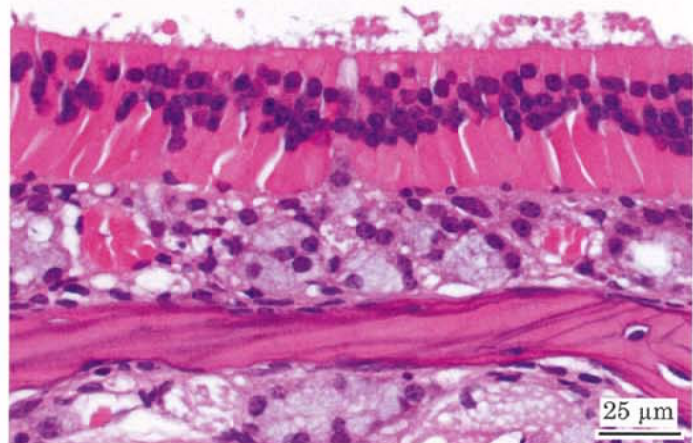
Photograph 1  
Nasal cavity (olfactory epithelium): Normal  
Mouse, Female, control, Animal No. 0832-2001 (H&E)



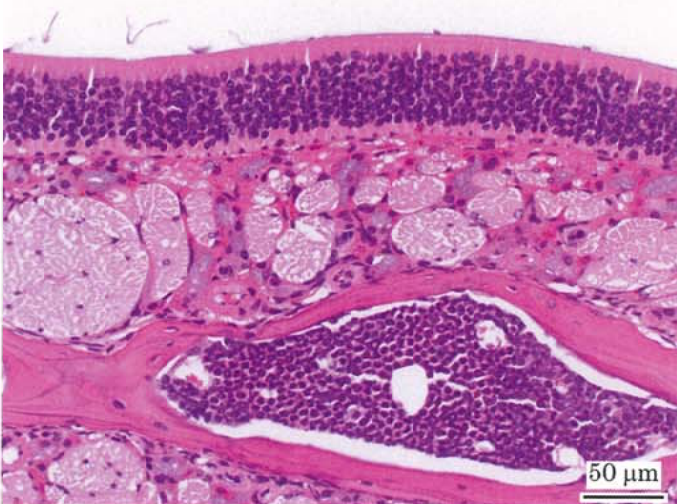
Photograph 2  
Nasal cavity: Atrophy of olfactory epithelium  
Mouse, Female, 10 ppm, Animal No. 0832-2201 (H&E)



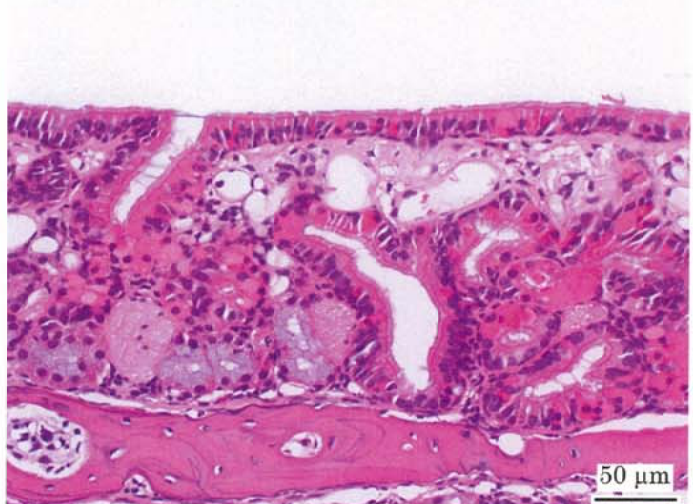
Photograph 3  
Nasal cavity: Regeneration of olfactory epithelium  
Mouse, Female, 10 ppm, Animal No. 0832-2201 (H&E)



Photograph 4  
Nasal cavity: Eosinophilic change of olfactory epithelium  
Mouse, Male, 40 ppm, Animal No. 0832-1301 (H&E)



Photograph 5  
Nasal cavity (olfactory epithelium): Normal  
Mouse, Male, control, Animal No. 0832-1005 (H&E)



Photograph 6  
Nasal cavity: respiratory metaplasia of olfactory epithelium  
and gland of lamina propria  
Mouse, Male, 40 ppm, Animal No. 0832-1301 (H&E)