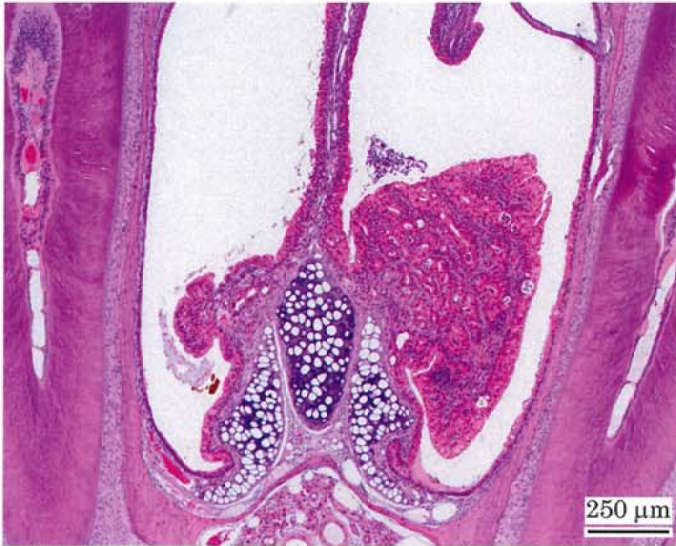

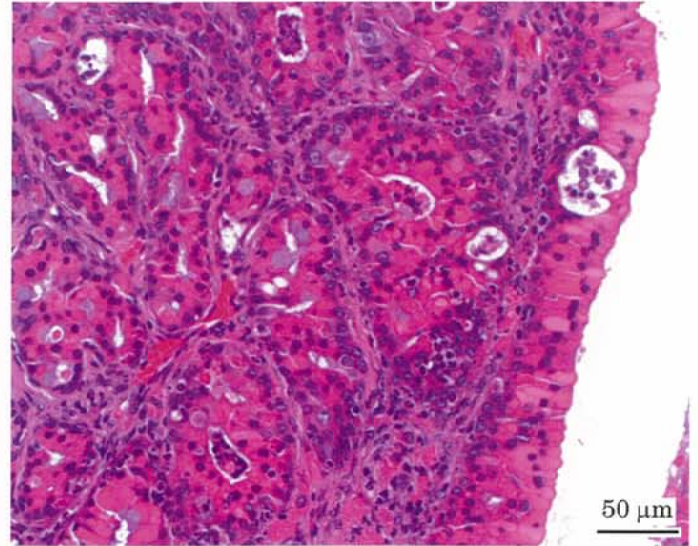
アクリロレインのマウスを用いた吸入によるがん原性試験報告書

試験番号：0817

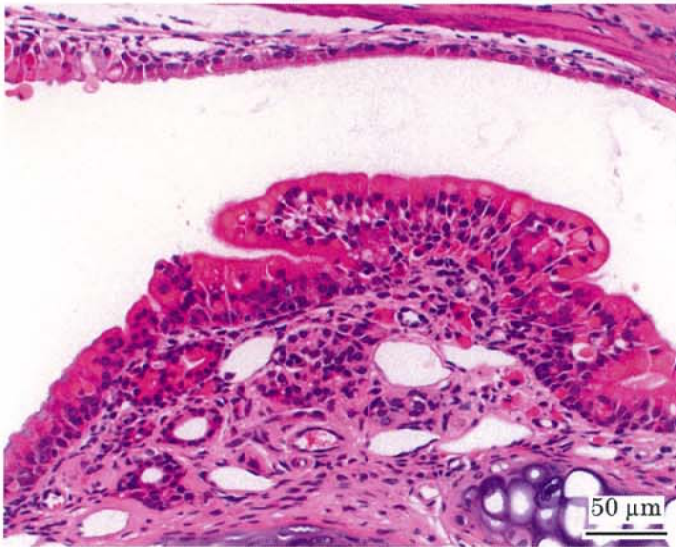
PHOTOGRAPHS



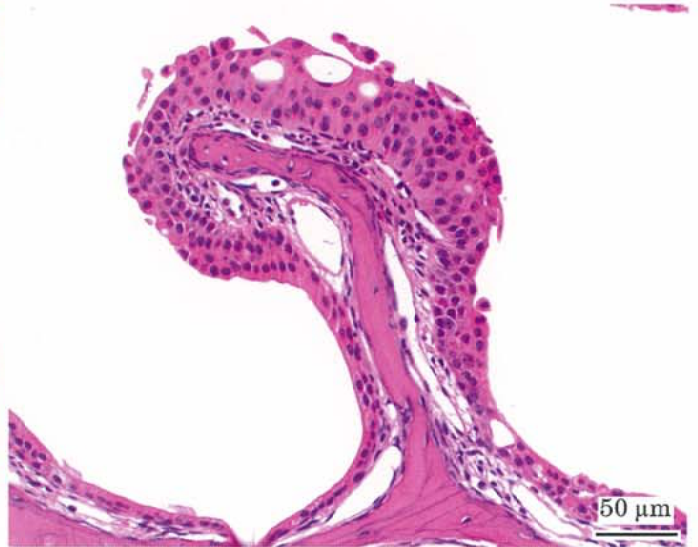Photograph 1
Nasal cavity: Adenoma
Mouse, Female, 1.6 ppm, Animal No. 0817-2308 (H&E)



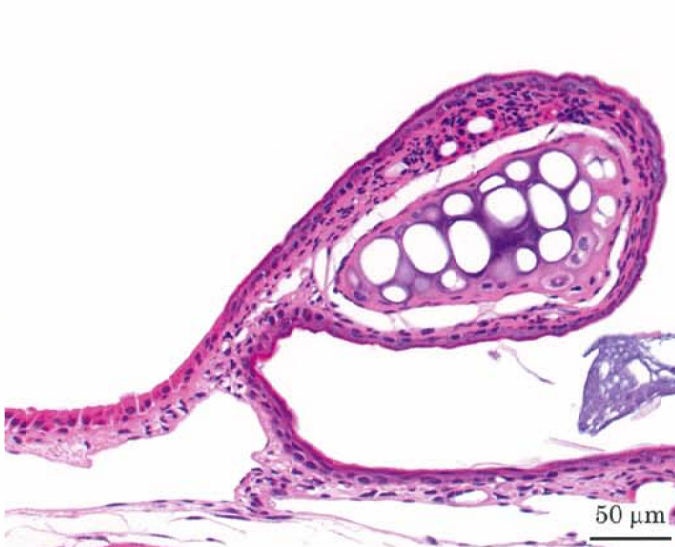Photograph 2
High magnification of photograph 1



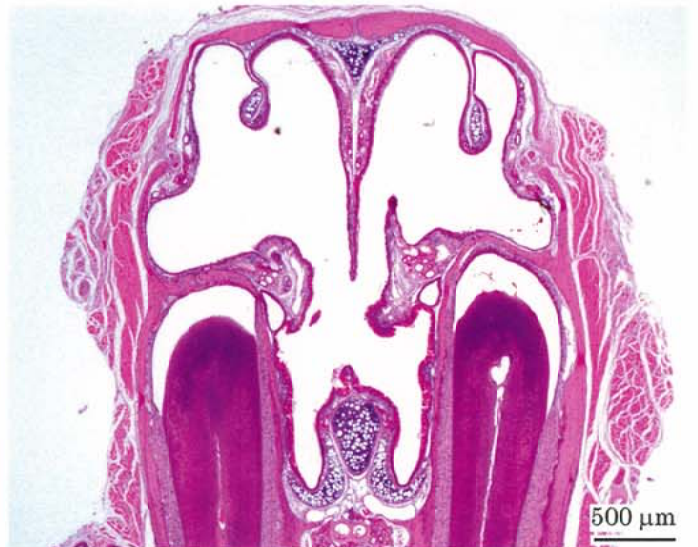Photograph 3
Nasal cavity: Hyperplasia of respiratory epithelium
Mouse, Female, 1.6 ppm, Animal No. 0817-2328 (H&E)



Photograph 4
Nasal cavity: Hyperplasia of transitional epithelium
Mouse, Male, 1.6 ppm, Animal No. 0817-1329 (H&E)



Photograph 5
Nasal cavity: Squamous metaplasia of respiratory epithelium
Mouse, Male, 1.6 ppm, Animal No. 0817-1306 (H&E)



Photograph 6
Nasal cavity: Atrophy of turbinate and septal perforation
Mouse, Male, 1.6 ppm, Animal No. 0817-1312 (H&E)