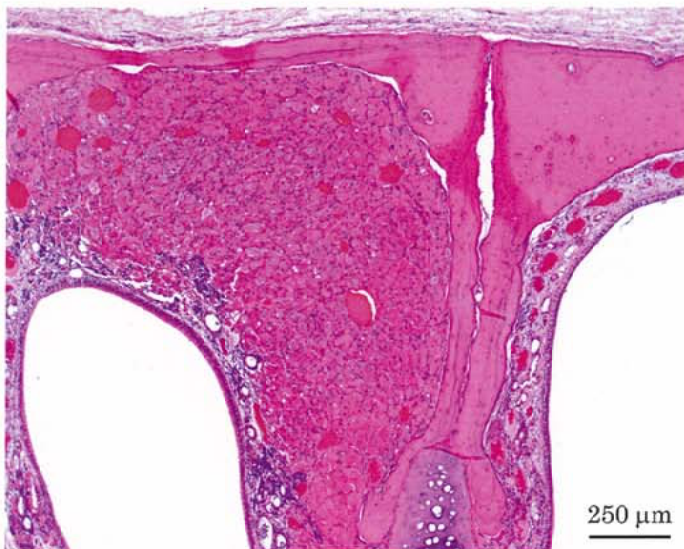

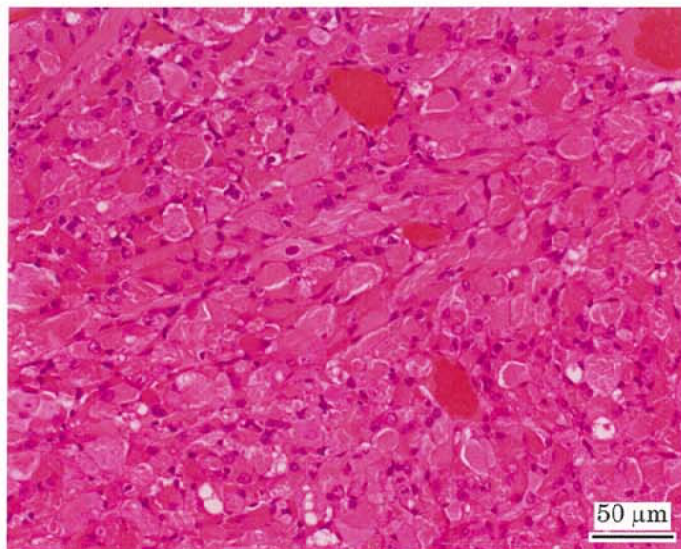
アクリロレインのラットを用いた吸入によるがん原性試験報告書

試験番号：0816

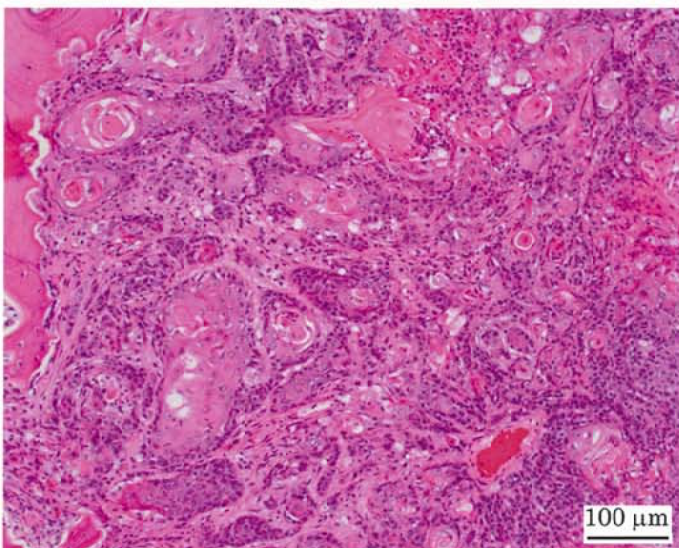
PHOTOGRAPHS



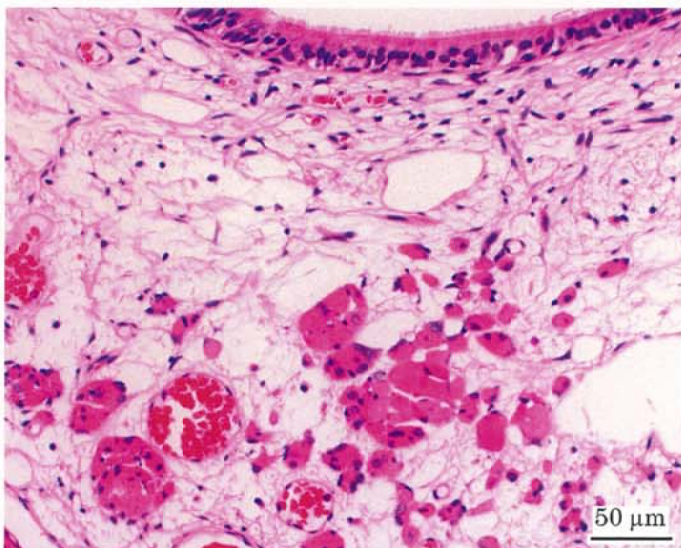
Photograph 1
Nasal cavity: Rhabdomyoma
Rat, Female, 2 ppm, Animal No. 0816-2345 (H&E)



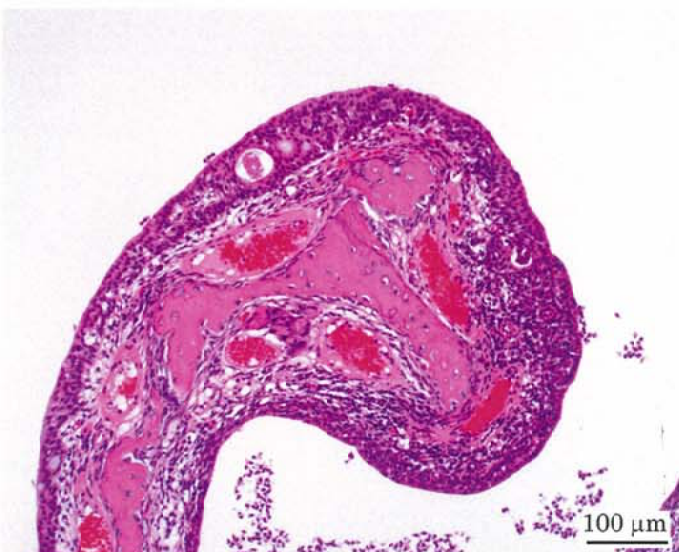Photograph 2
High magnification of photograph 1



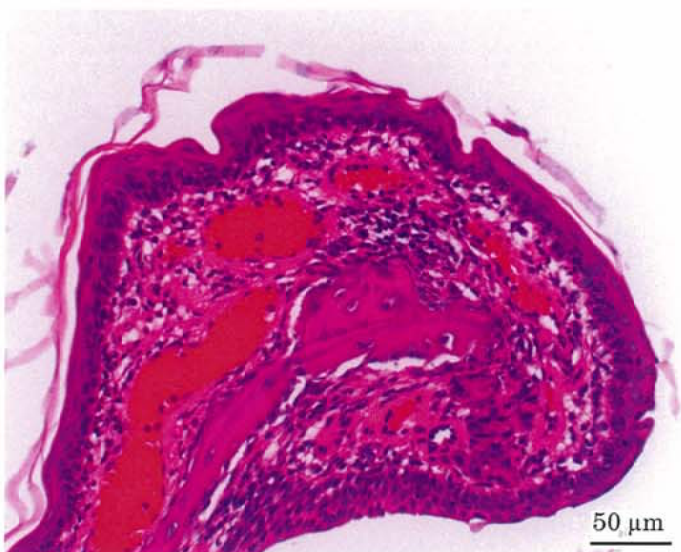Photograph 3
Nasal cavity: Squamous cell carcinoma
Rat, Female, 2 ppm, Animal No. 0816-2304 (H&E)



Photograph 4
Nasal cavity: proliferation of striated muscle, edema and respiratory metaplasia of olfactory epithelium
Rat, Male, 2 ppm, Animal No. 0816-1302 (H&E)



Photograph 5
Nasal cavity: Hyperplasia of transitional epithelium
Rat, Male, 2 ppm, Animal No. 0816-1339 (H&E)



Photograph 6
Nasal cavity: Squamous cell metaplasia of respiratory epithelium
Rat, Female, 2 ppm, Animal No. 0816-2340 (H&E)