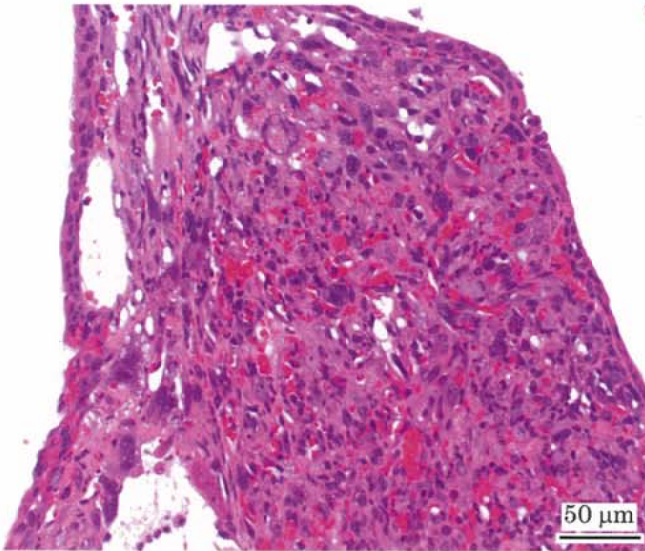


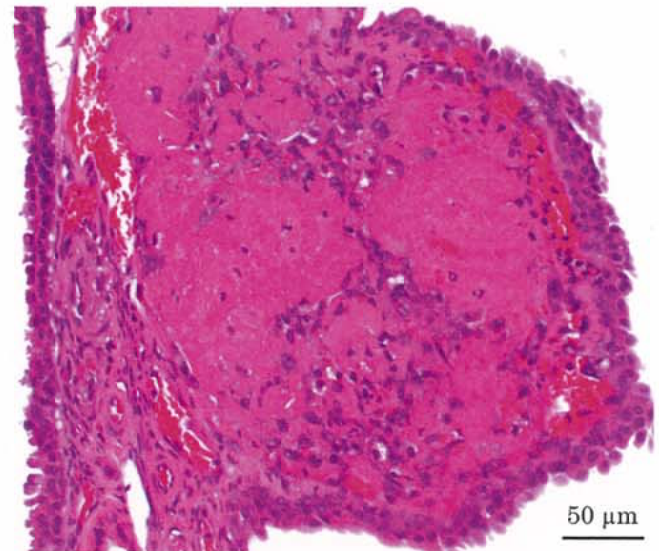
メタクリル酸 = 2,3 エポキシプロピルのマウスを用いた  
吸入によるがん原性試験報告書

試験番号 : 0795

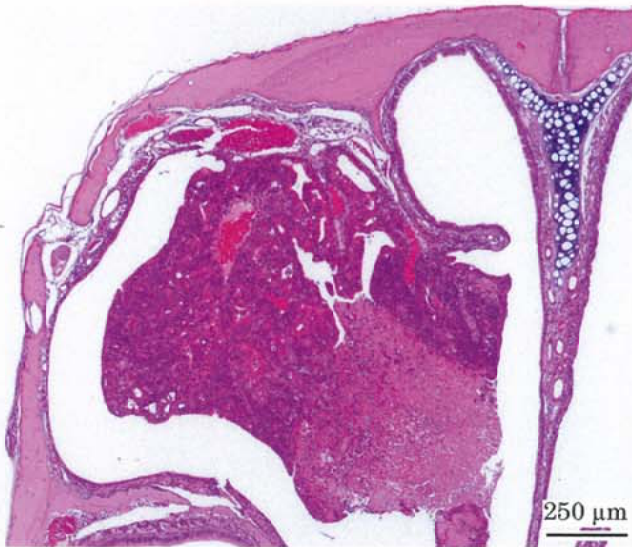# PHOTOGRAPHS



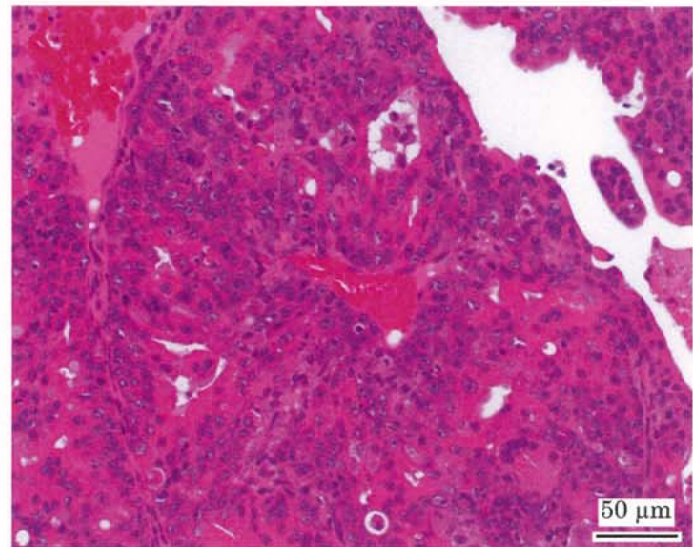
Photograph 1  
Nasal cavity: Hemangiosarcoma  
Mouse, Male, 10 ppm, Animal No. 0795-1336 (H&E)



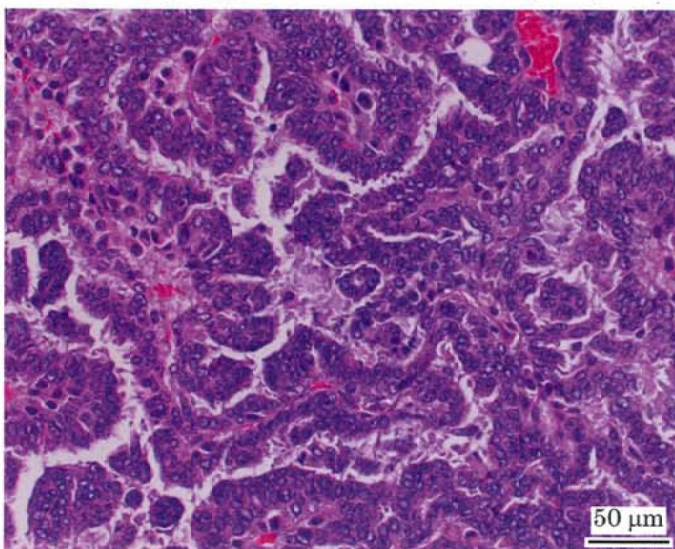
Photograph 2  
Nasal cavity: Hemangioma  
Mouse, Male, 10 ppm, Animal No. 0795-1307 (H&E)



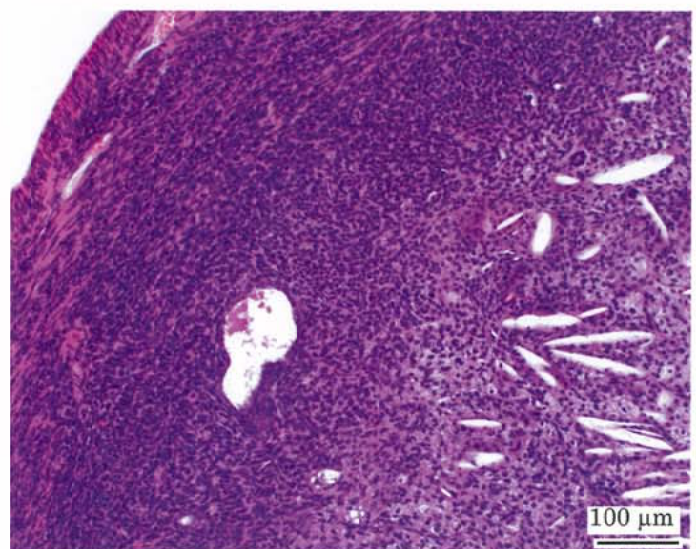
Photograph 3  
Nasal cavity: Adenocarcinoma  
Mouse, Female, 10 ppm, Animal No. 0795-2302 (H&E)



Photograph 4  
High magnification of photograph 3



Photograph 5  
Lung: Bronchiolar-alveolar carcinoma  
Mouse, Female, 10 ppm, Animal No. 0795-2318 (H&E)



Photograph 6  
Uterus: Histiocytic sarcoma  
Mouse, Female, 10 ppm, Animal No. 0795-2301 (H&E)