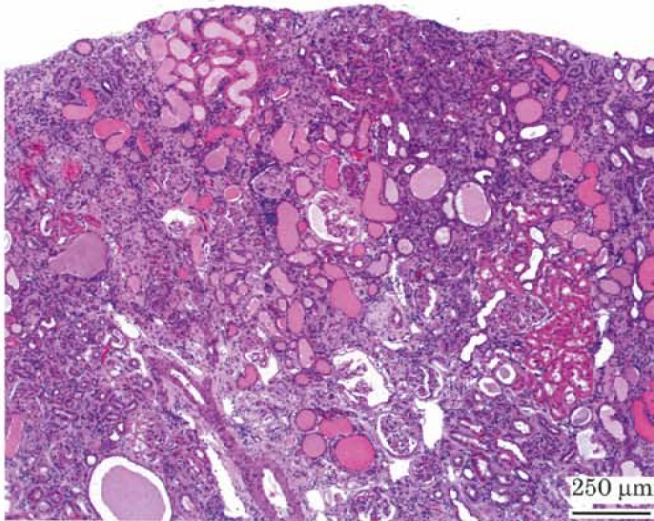


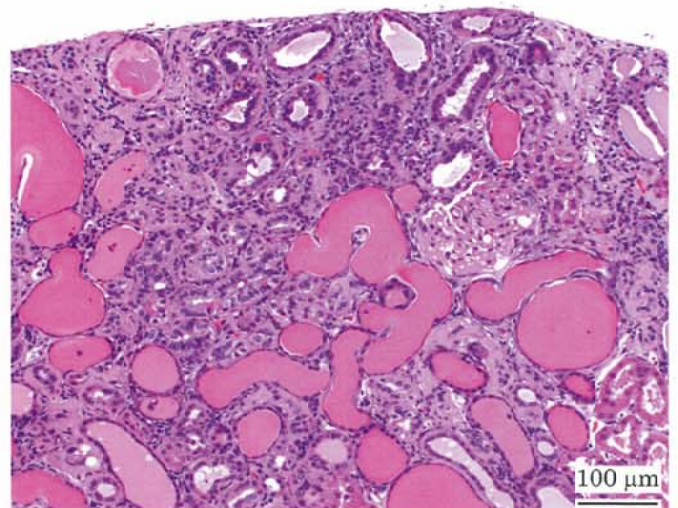
4-クロロ-2-ニトロアニリンのラットを用いた
経口投与によるがん原性試験（混餌試験）報告書

試験番号：0759

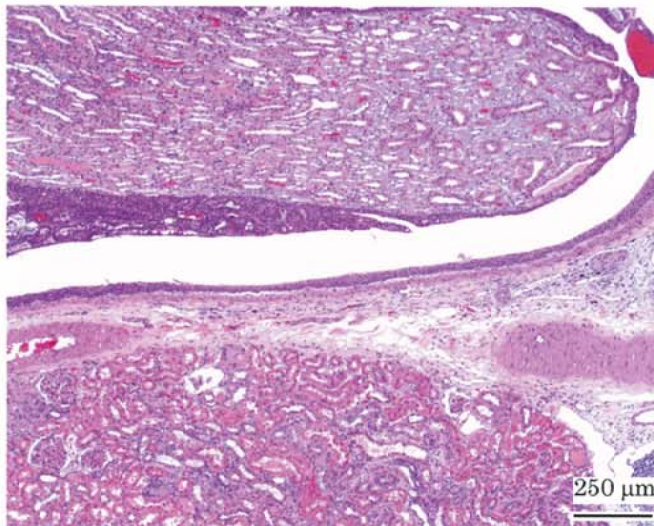
PHOTOGRAPHS



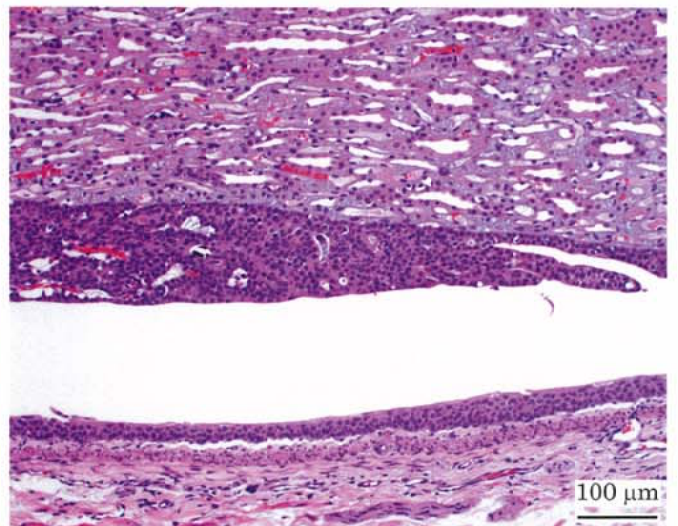
Photograph 1
Kidney: Chronic nephropathy
Rat, Male, 7000 ppm, Animal No. 0759-1307 (H&E)



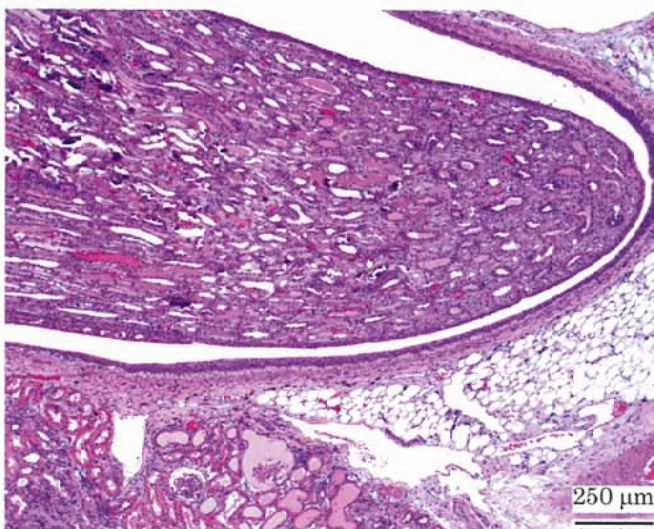Photograph 2
Kidney: Chronic nephropathy (higher magnification)
Rat, Male, 7000 ppm, Animal No. 0759-1307 (H&E)



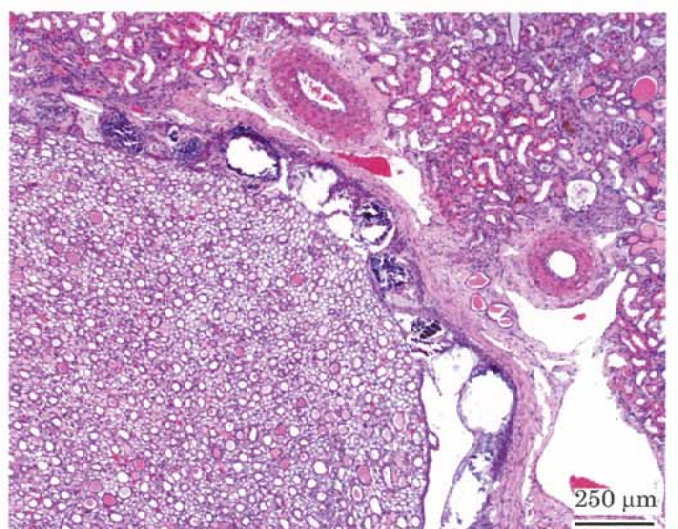
Photograph 3
Kidney: Urothelial hyperplasia of pelvis
Rat, Male, 7000 ppm, Animal No. 0759-1324 (H&E)



Photograph 4
Kidney: Urothelial hyperplasia of pelvis (higher magnification)
Rat, Male, 7000 ppm, Animal No. 0759-1324 (H&E)



Photograph 5
Kidney: Mineralization of papilla
Rat, Male, 7000 ppm, Animal No. 0759-1307 (H&E)



Photograph 6
Kidney: Mineralization of pelvis
Rat, Female, 4000 ppm, Animal No. 0759-2301 (H&E)