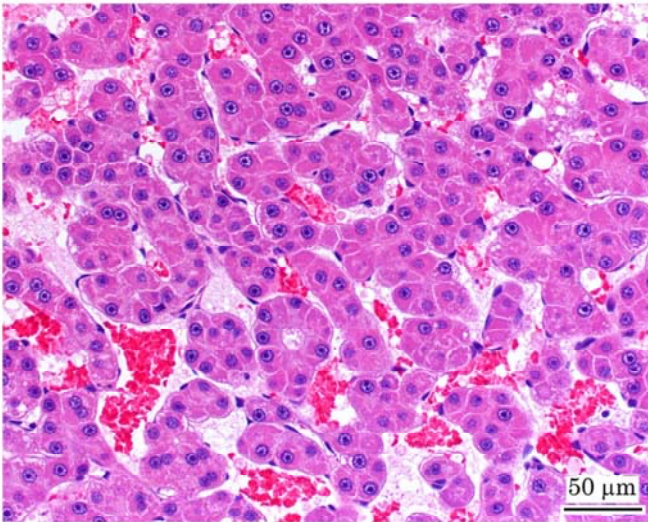


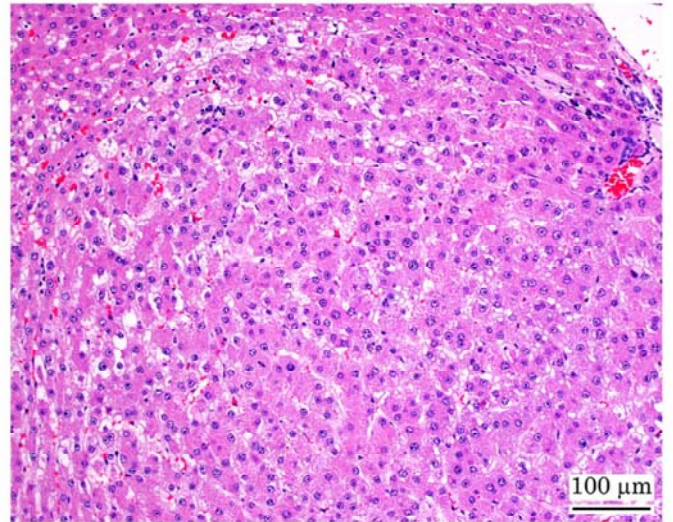
N,N-ジメチルアセトアミドのラットを用いた
吸入によるがん原性試験報告書

試験番号：0753

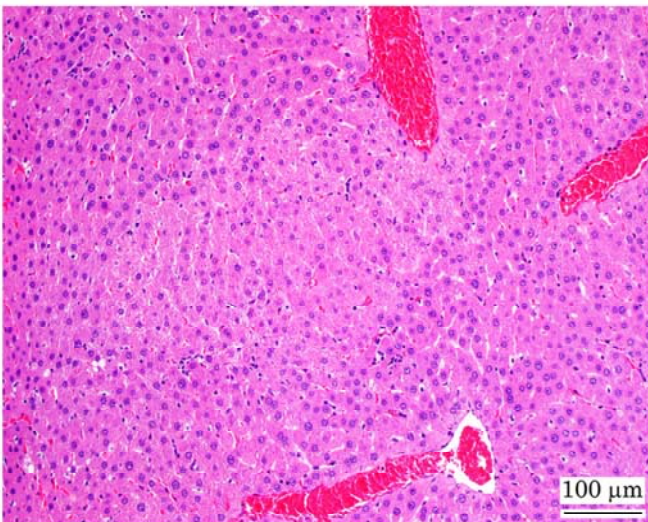
PHOTOGRAPHS



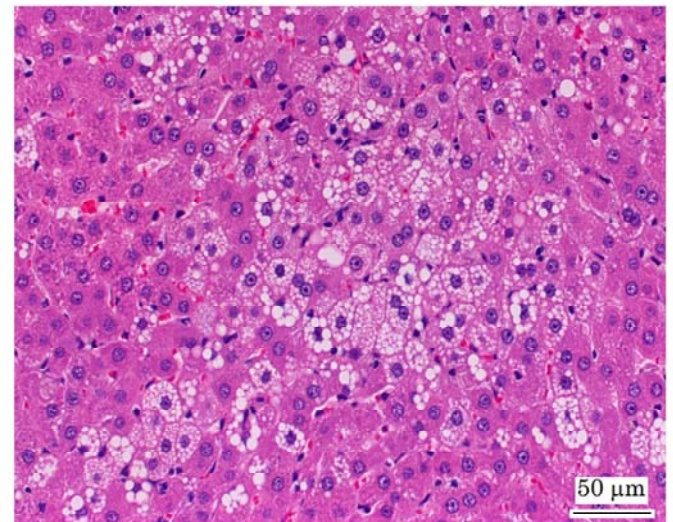
Photograph 1
Liver: Hepatocellular carcinoma
Rat, Male, 450 ppm, Animal No. 0753-1346 (H&E)



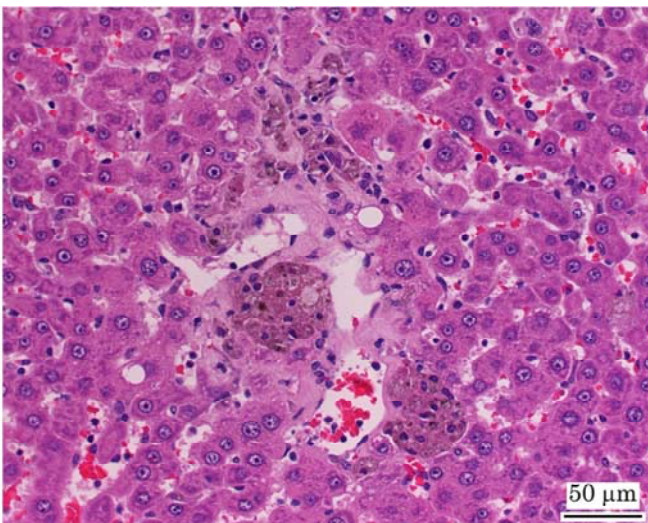
Photograph 2
Liver: Hepatocellular adenoma
Rat, Male, 450 ppm, Animal No. 0753-1301 (H&E)



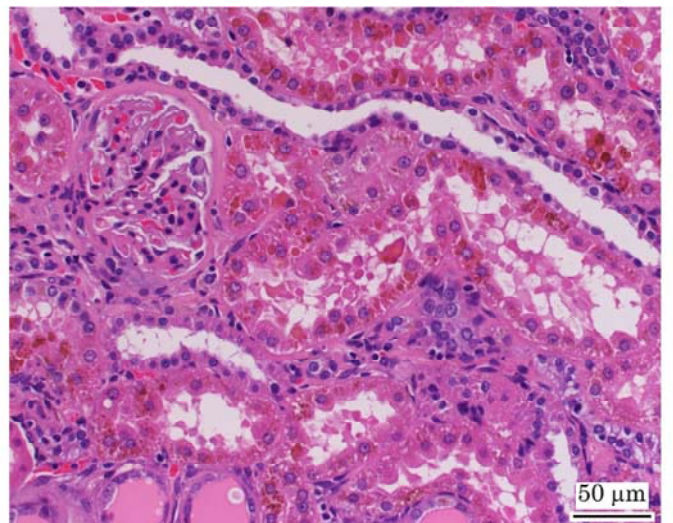
Photograph 3
Liver: Acidophilic cell focus
Rat, Male, 450 ppm, Animal No. 0753-1313 (H&E)



Photograph 4
Liver: Focal fatty change
Rat, Male, 450 ppm, Animal No. 0753-1348 (H&E)



Photograph 5
Liver: Deposit of brown pigment and granulation
Rat, Female, 450 ppm, Animal No. 0753-2336 (H&E)



Photograph 6
Kidney: Deposit of brown pigment in the proximal tubule
Rat, Male, 450 ppm, Animal No. 0753-1305 (H&E)