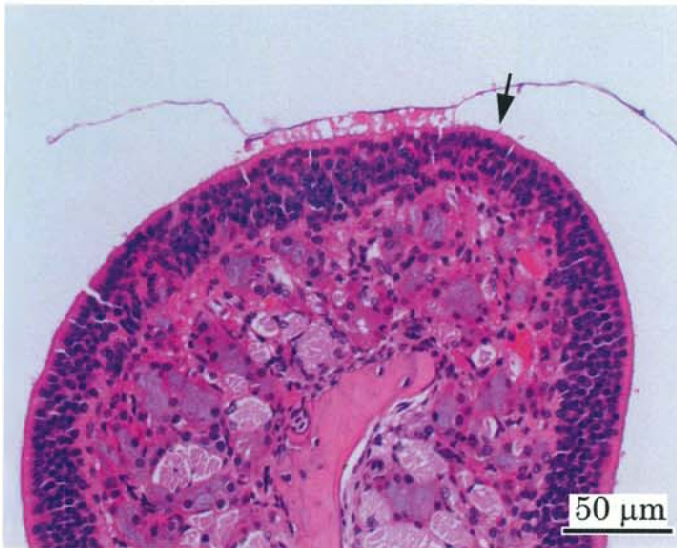

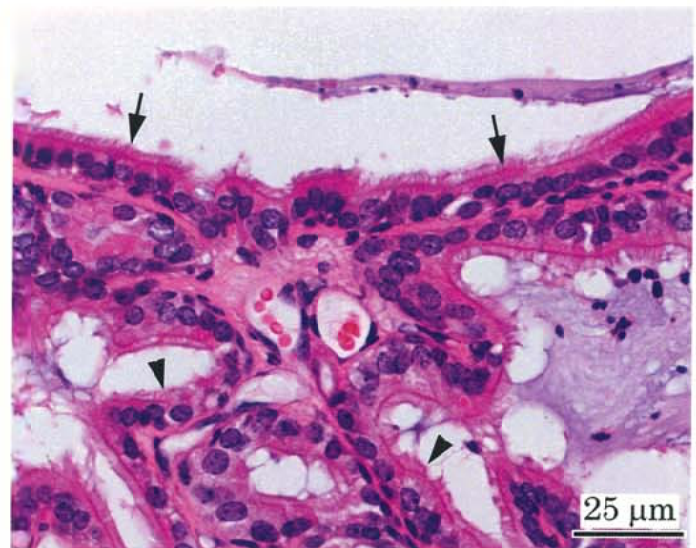
アクリル酸のマウスを用いた
吸入によるがん原性試験報告書

試験番号：0705

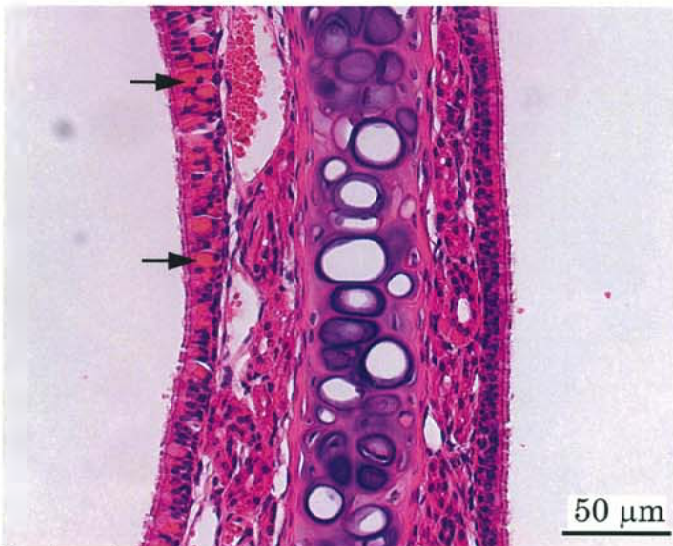
PHOTOGRAPHS



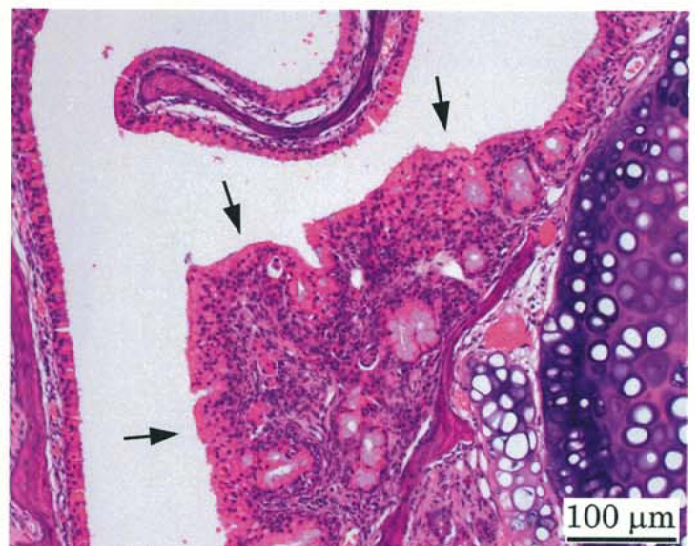Photograph 1
Nasal cavity (Level 3): Atrophy of olfactory epithelium (arrow)
Mouse, Male, 32 ppm, Animal No. 0705-1305 (H&E)



Photograph 2
Nasal cavity (Level 3): Respiratory metaplasia of olfactory epithelium (arrows) and gland (arrow heads)
Mouse, Male, 32 ppm, Animal No. 0705-1342 (H&E)



Photograph 3
Nasal cavity (Level 2): Eosinophilic change of respiratory epithelium (arrows, left side) and normal epithelium (right side)
Mouse, Male, 32 ppm, Animal No. 0705-1350 (H&E)



Photograph 4
Nasal cavity (Level 1): Hyperplasia of respiratory epithelium (arrows)
Mouse, Female, 32 ppm, Animal No. 0705-2306 (H&E)