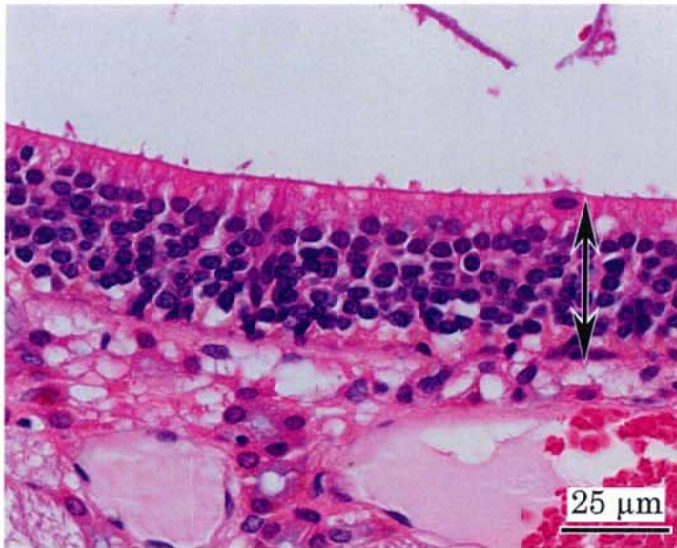


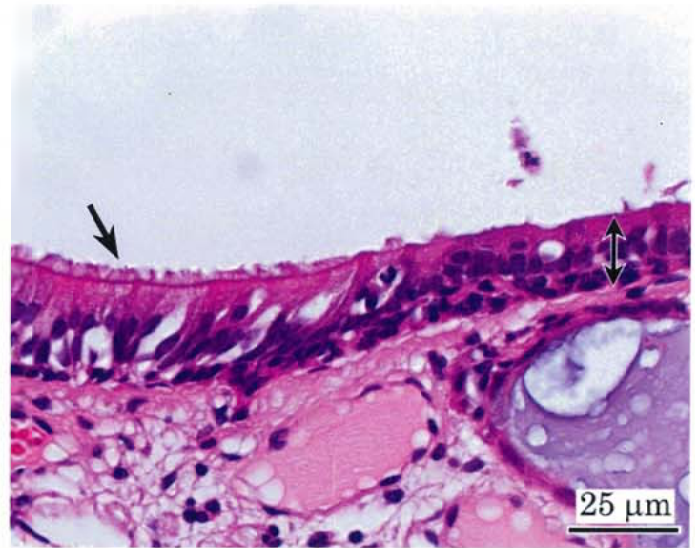
アクリル酸のラットを用いた
吸入によるがん原性試験報告書

試験番号：0704

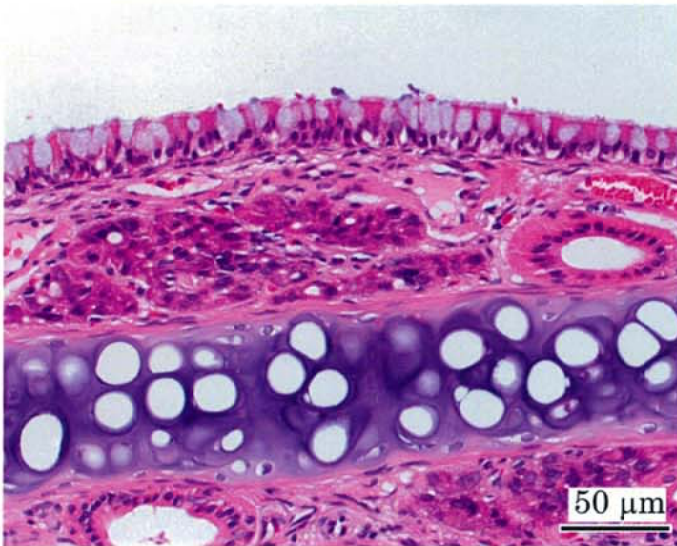
PHOTOGRAPHS



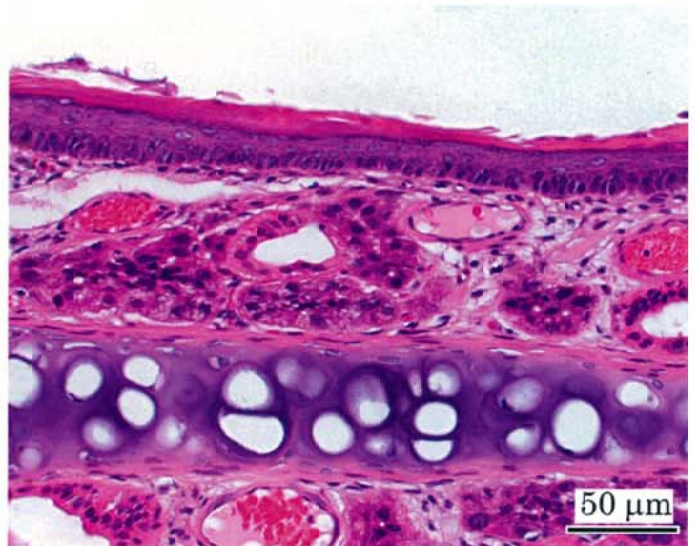Photograph 1
Nasal cavity (Level 2): Normal, olfactory epithelium (double-headed arrow)
Rat, Male, Control, Animal No. 0704-1011 (H&E)



Photograph 2
Nasal cavity (Level 2): Atrophy (double-headed arrow) and respiratory metaplasia (arrow) of olfactory epithelium
Rat, Male, 160 ppm, Animal No. 0704-1304 (H&E)



Photograph 3
Nasal cavity (Level 1): Normal, respiratory epithelium
Rat, Male, Control, Animal No. 0704-1011 (H&E)



Photograph 4
Nasal cavity (Level 1): Squamous metaplasia of olfactory epithelium
Rat, Male, 160 ppm, Animal No. 0704-1302 (H&E)