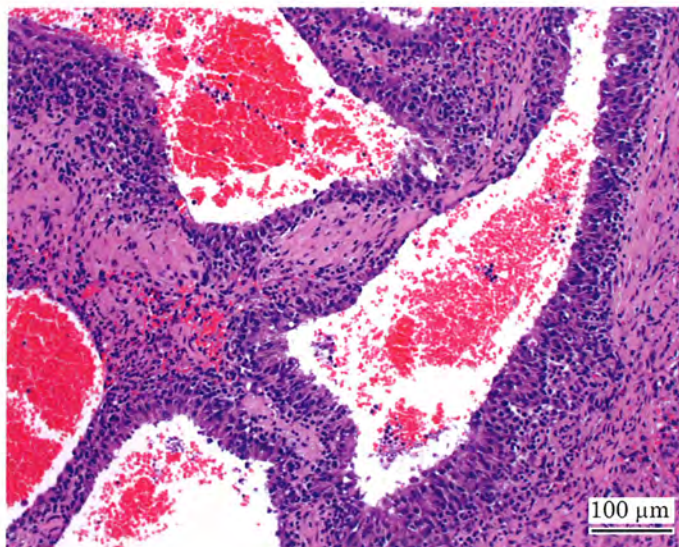


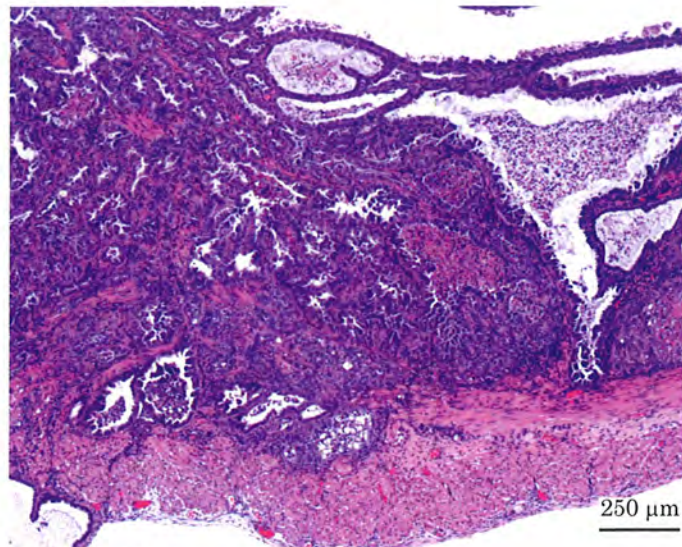
ジフェニルアミンのラットを用いた  
経口投与によるがん原性試験（混餌試験）報告書

試験番号：0684

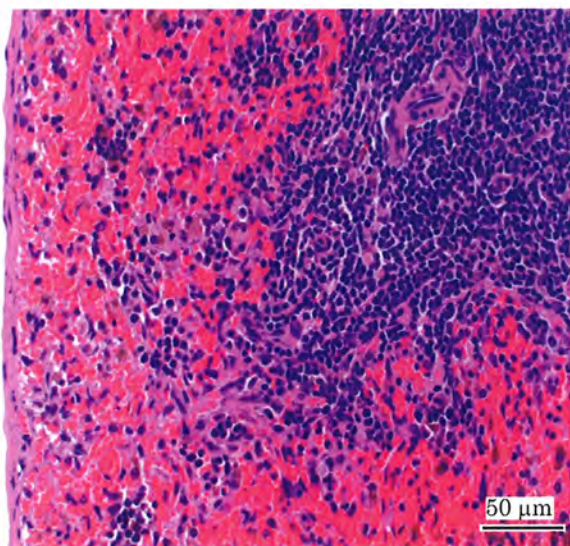
PHOTOGRAPHS



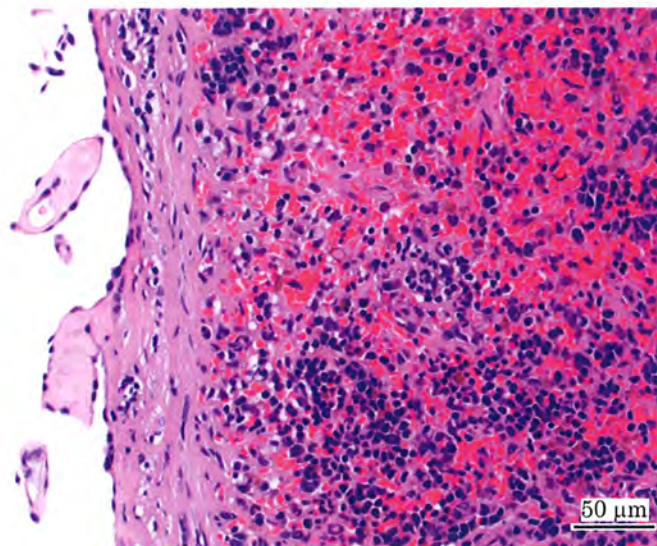
Photograph 1  
Spleen: Hemangiosarcoma  
Rat, Male, 4000 ppm, Animal No. 0684-1343 (H&E)



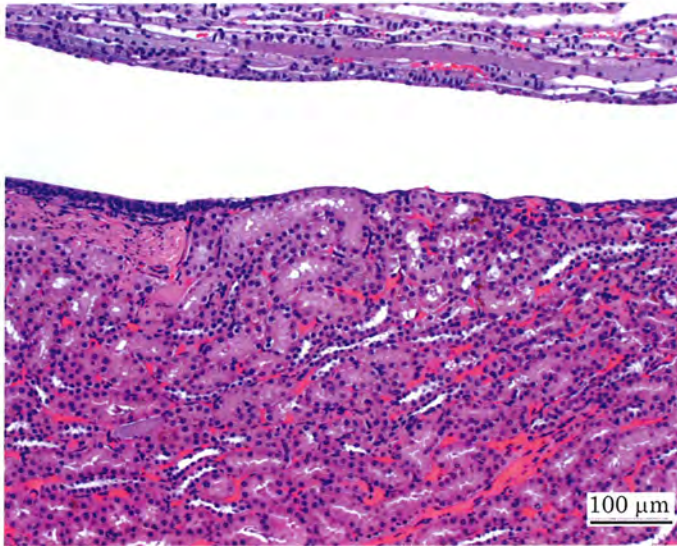
Photograph 2  
Uterus: Adenocarcinoma  
Rat, Female, 4000 ppm, Animal No. 0684-2320 (H&E)



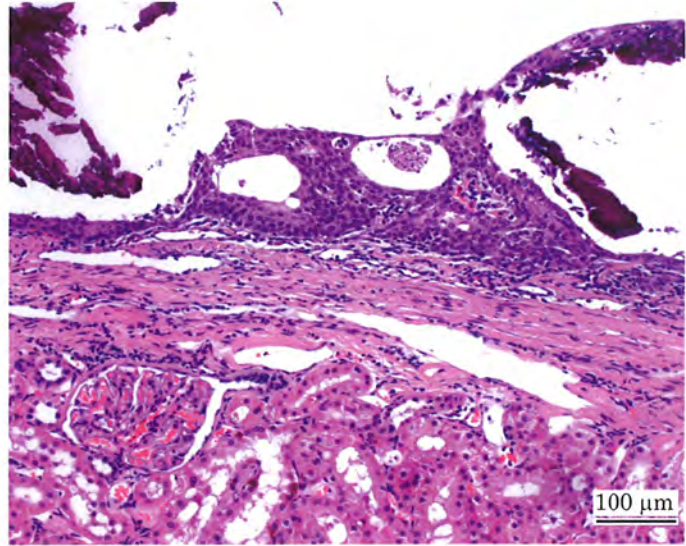
Photograph 3  
Spleen: Normal  
Rat, Male, Control, Animal No. 0684-1016 (H&E)



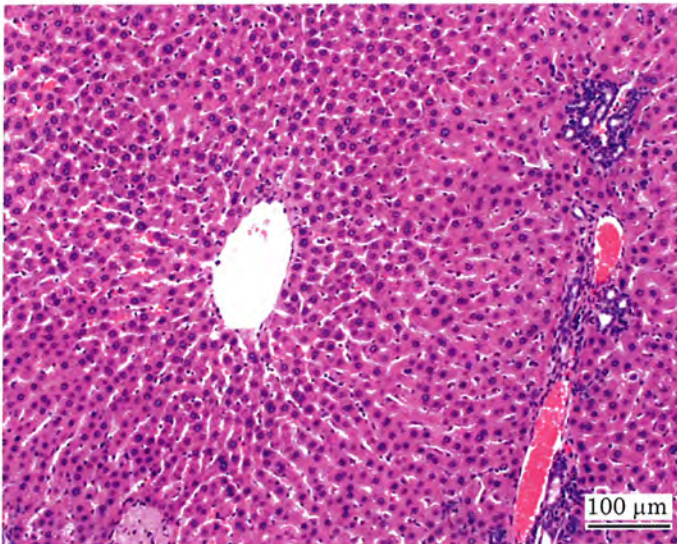
Photograph 4  
Spleen: Capsule hyperplasia, extramedullary hematopoiesis,  
deposit of hemosiderin  
Rat, Male, 4000 ppm, Animal No. 0684-1317 (H&E)



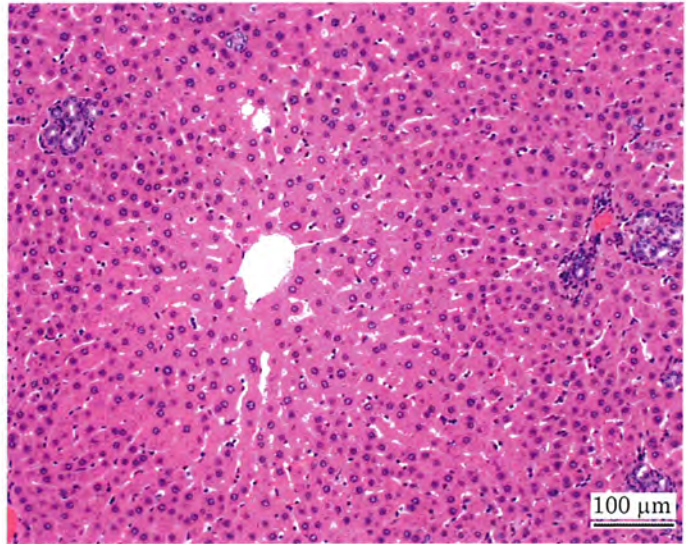
Photograph 5  
Kidney: Normal  
Rat, Male, Control, Animal No. 0684-1026 (H&E)



Photograph 6  
Kidney: Urothelial hyperplasia:pelvis, mineralization:pelvis  
Rat, Male, 4000 ppm, Animal No. 0684-1318 (H&E)



Photograph 7  
Liver: Normal  
Rat, Male, Control, Animal No. 0684-1022 (H&E)



Photograph 8  
Liver: Hepatocellular hypertrophy: central  
Rat, Male, 4000 ppm, Animal No. 0684-1316 (H&E)