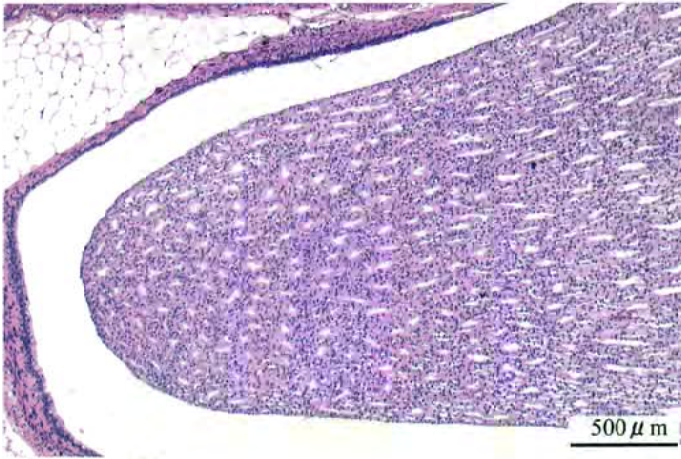


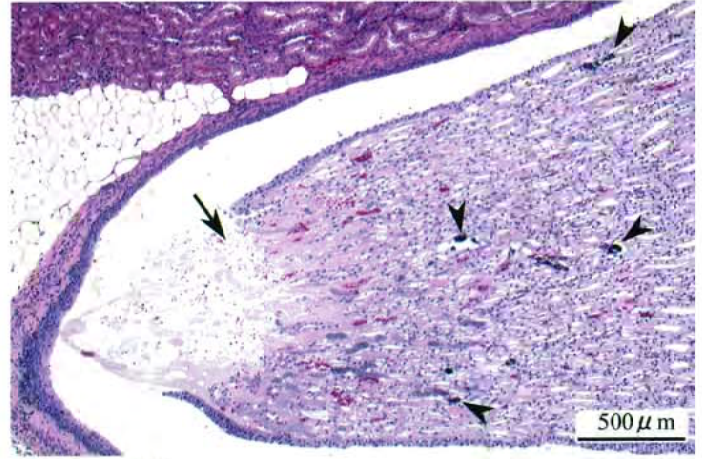
2-メチル-1-プロパノールのラットを用いた
経口投与によるがん原性試験（混水試験）報告書

試験番号：0612

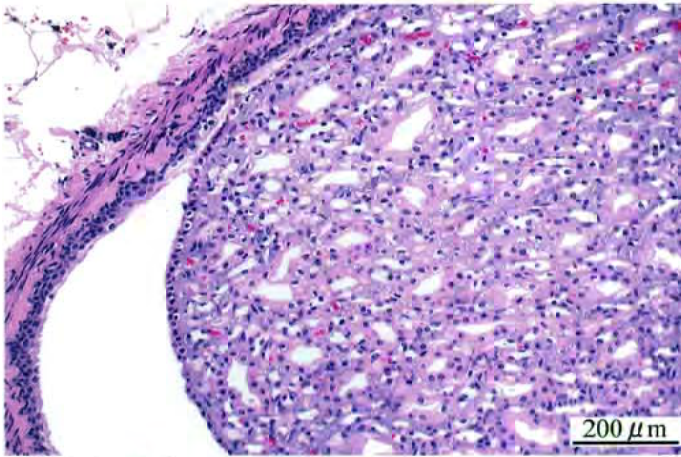
PHOTOGRAPHS



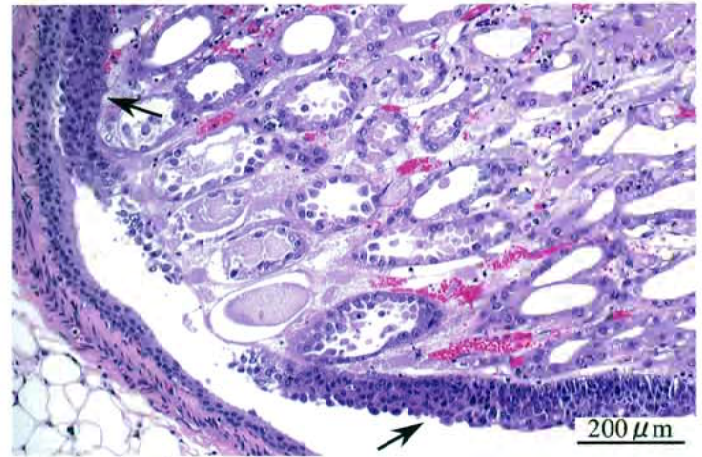
Photograph 1
Kidney: Normal
Rat, Female, Control, Animal No. 0612-2012 (H&E)



Photograph 2
Kidney: Papillary necrosis (Arrow), Mineralization of papilla (Arrowheads)
Rat, Female, 30000ppm, Animal No. 0612-2346 (H&E)



Photograph 3
Kidney: Normal
Rat, Female, Control, Animal No. 0612-2036 (H&E)



Photograph 4
Kidney: Urothelial hyperplasia of pelvis (Arrows)
Rat, Female, 30000ppm, Animal No. 0612-2337 (H&E)