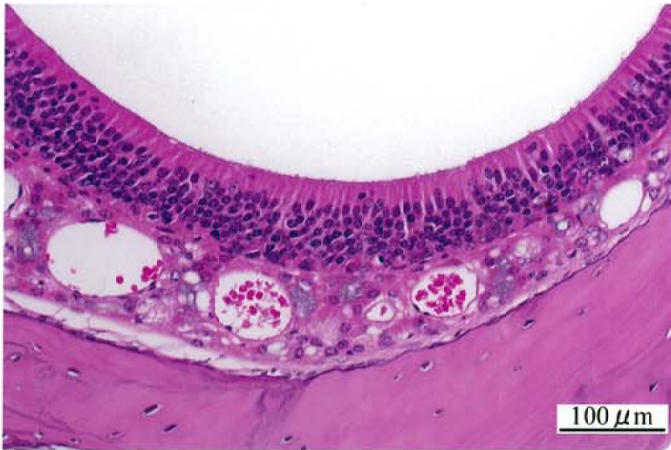

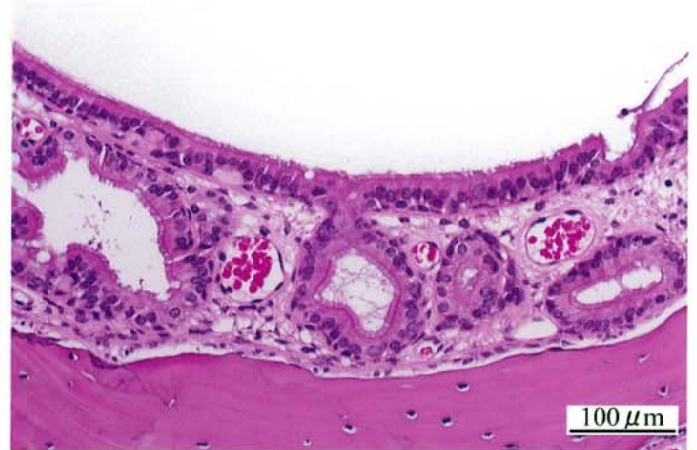酢酸イソプロピルのマウスを用いた  
吸入によるがん原性試験報告書

試験番号：0611

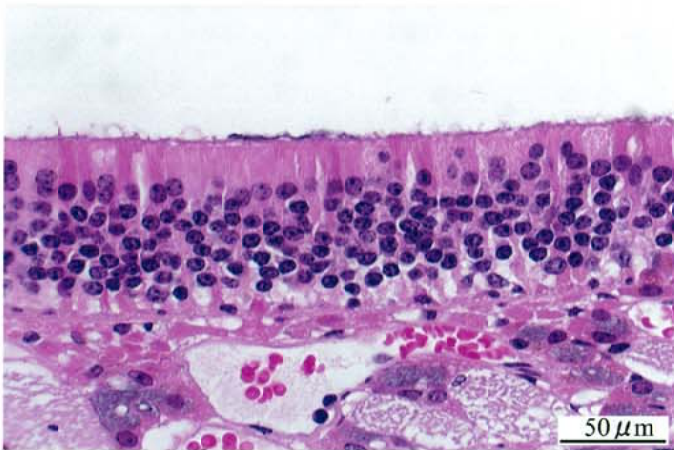
# PHOTOGRAPHS



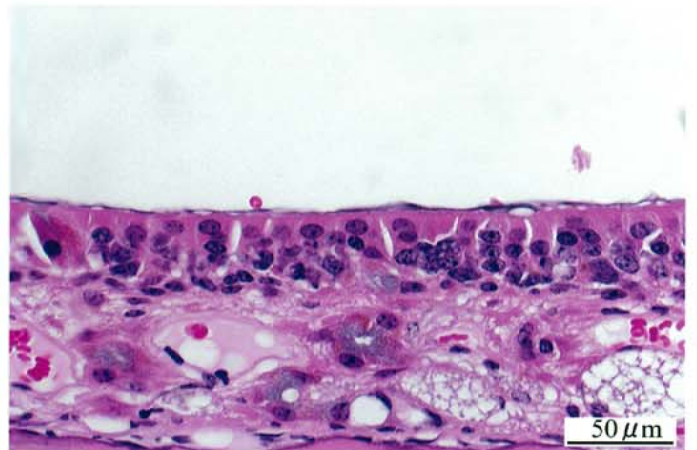
Photograph 1  
Nasal cavity: Normal  
Mouse, Male, Control, Animal No. 0611-1013 (H&E)



Photograph 2  
Nasal cavity: respiratory metaplasia of the olfactory epithelium  
and submucosal gland  
Mouse, Male, 4000 ppm, Animal No. 0611-1327 (H&E)



Photograph 3  
Nasal cavity: Normal  
Mouse, Male, Control, Animal No. 0611-1002 (H&E)



Photograph 4  
Nasal cavity: atrophy of the olfactory epithelium  
Mouse, Male, 2000 ppm, Animal No. 0611-1201 (H&E)