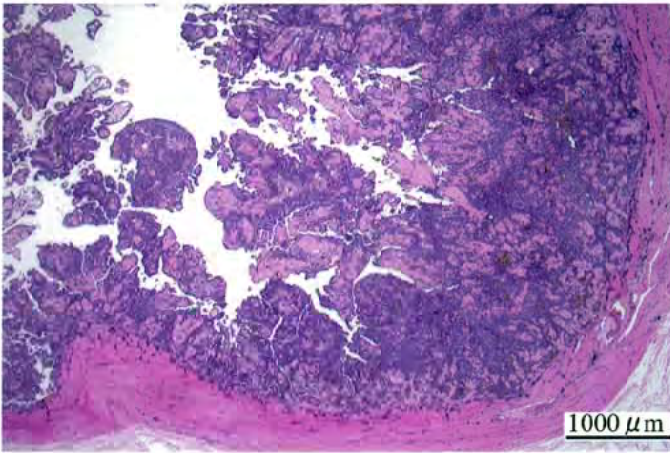


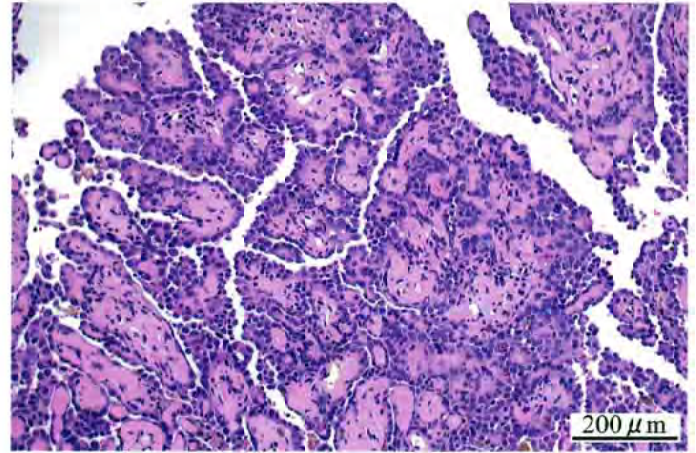
酢酸イソプロピルのラットを用いた
吸入によるがん原性試験報告書

試験番号：0610

PHOTOGRAPHS



Photograph 1
Peritoneum: mesothelioma
Rat, Male, 4000 ppm, Animal No. 0610-1336 (H&E)



Photograph 2
Higher magnification of photograph 1
Peritoneum: mesothelioma
Rat, Male, 4000 ppm, Animal No. 0610-1336 (H&E)