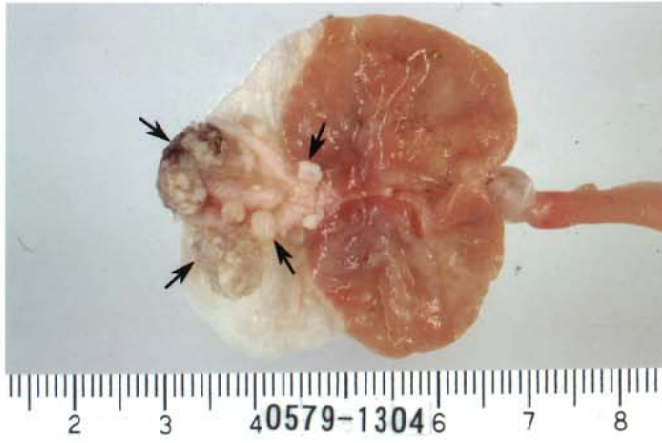

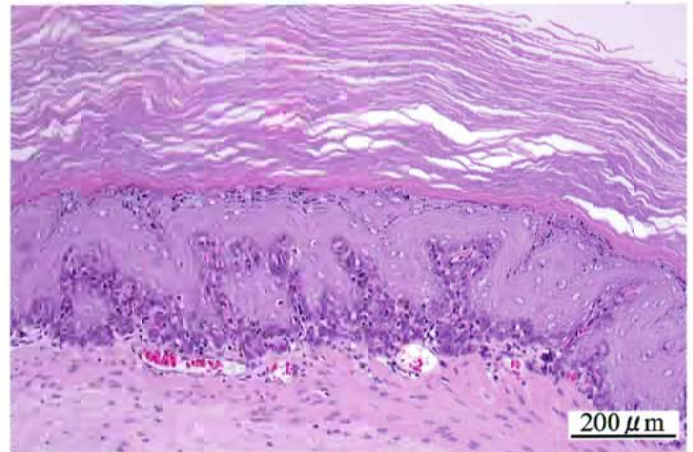
2-アミノ-4-クロロフェノールのラットを用いた
経口投与によるがん原性試験（混餌試験）報告書

試験番号：0579

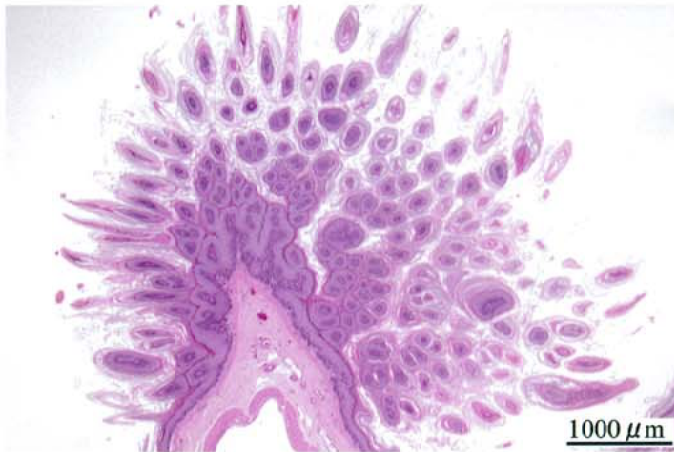PHOTOGRAPHS



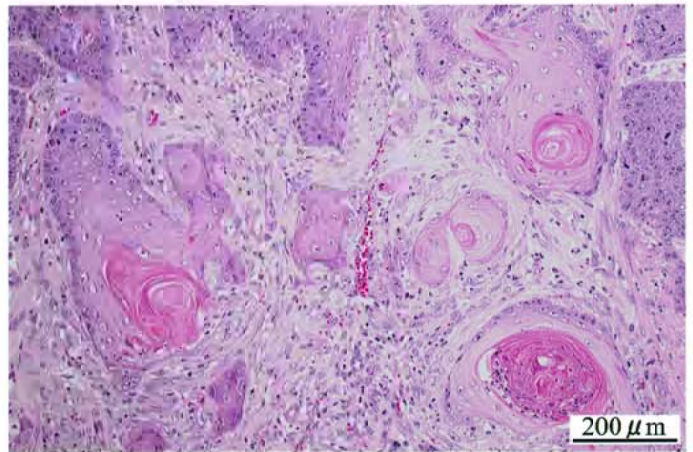
Photograph 1
Forestomach: nodule (arrows)
Rat, Male, 8000 ppm, Animal No. 0579-1304



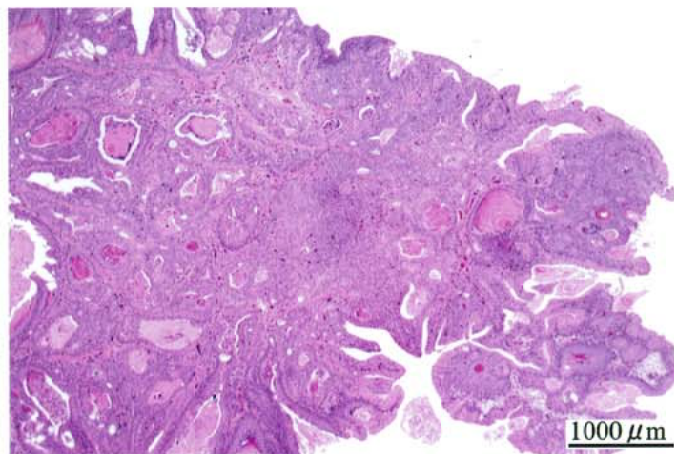
Photograph 2
Forestomach: Squamous cell hyperplasia
Rat, Male, 8000 ppm, Animal No. 0579-1340 (H&E)



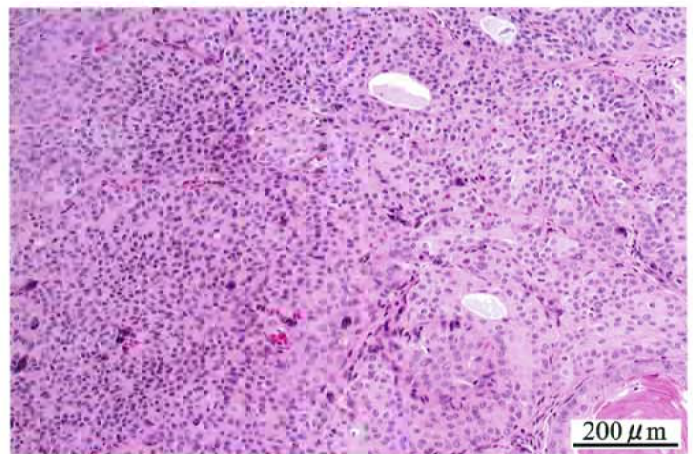
Photograph 3
Forestomach: Squamous cell papilloma
Rat, Male, 8000 ppm, Animal No. 0579-1336 (H&E)



Photograph 4
Forestomach: Squamous cell carcinoma
Rat, Male, 8000 ppm, Animal No. 0579-1344 (H&E)



Photograph 5
Urinary bladder: Transitional cell carcinoma
Rat, Male, 8000 ppm, Animal No. 0579-1329 (H&E)



Photograph 6
Higher magnification of photograph 5
Urinary bladder: Transitional cell carcinoma
Rat, Male, 8000 ppm, Animal No. 0579-1329 (H&E)