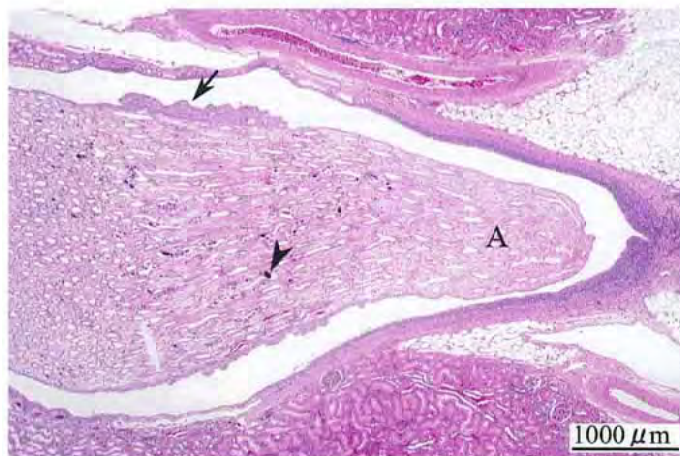


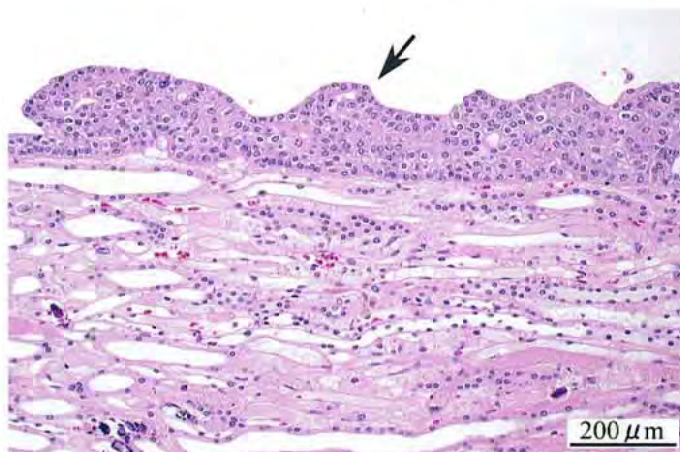
2-フェノキシエタノールのラットを用いた
経口投与によるがん原性試験（混水試験）報告書

試験番号：0497

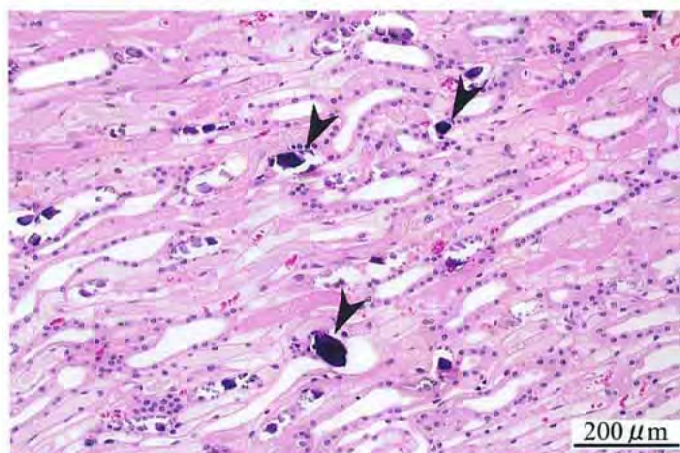
PHOTOGRAPHS



Photograph 1
Kidney: urothelial hyperplasia (arrow) and mineralization (arrowhead) of pelvis, and papillary necrosis (A)
Rat, Male, 10000 ppm, Animal No. 0497-1304 (H&E)



Photograph 2
Higher magnification of photograph 1
Kidney: urothelial hyperplasia of pelvis (arrow)
Rat, Male, 10000 ppm, Animal No. 0497-1304 (H&E)



Photograph 3
Higher magnification of photograph 1
Kidney: mineralization of pelvis (arrowheads)
Rat, Male, 10000 ppm, Animal No. 0497-1304 (H&E)