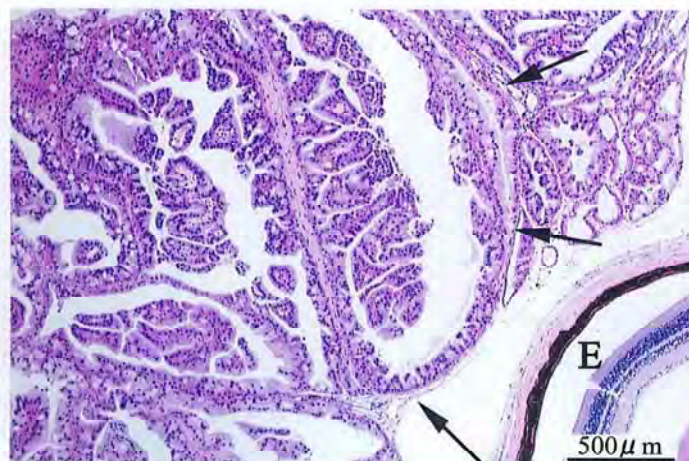


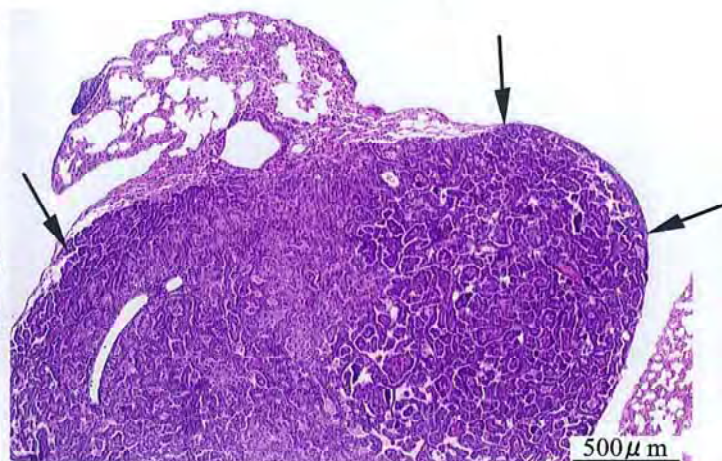
1,2-ジクロロプロパンのマウスを用いた  
吸入によるがん原性試験報告書

試験番号：0458

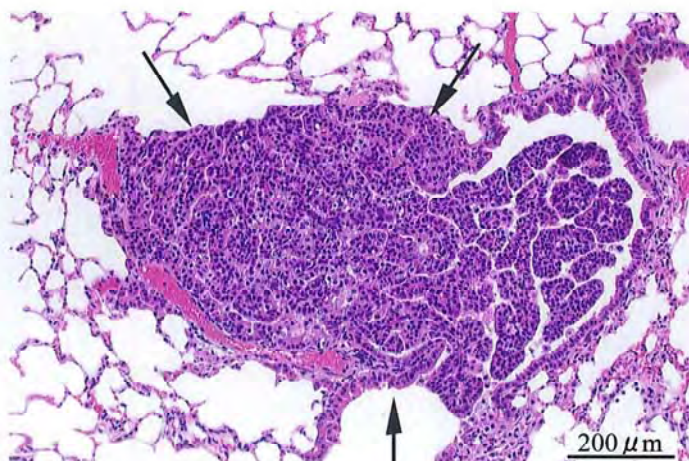
# PHOTOGRAPHS



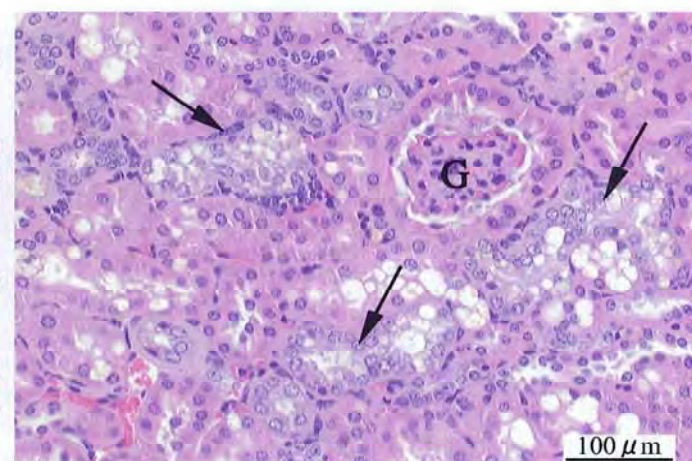
Photograph 1  
Harderian gland: Adenoma (Arrows), Eye (E)  
Mouse, Male, 200 ppm, Animal No. 0458-1310 (H&E)



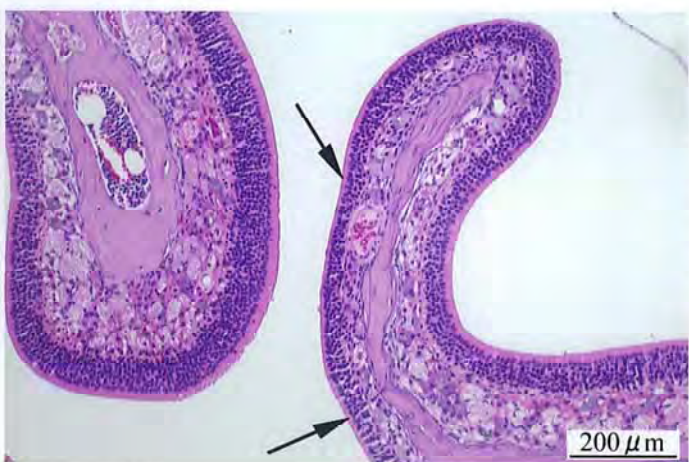
Photograph 2  
Lung: Bronchiolar-alveolar carcinoma (Arrows)  
Mouse, Female, 200 ppm, Animal No. 0458-2306 (H&E)



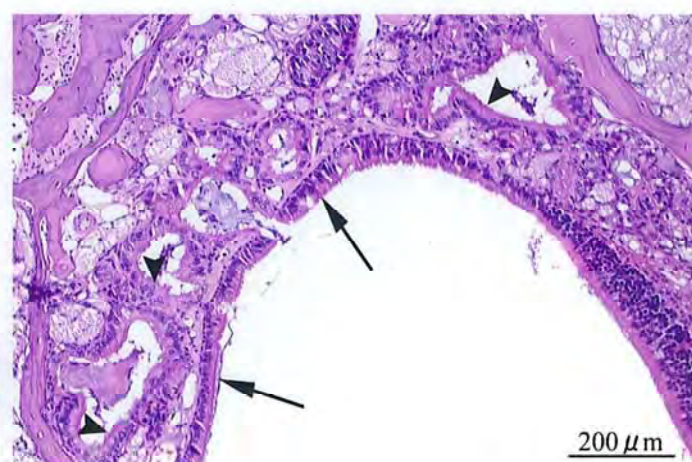
Photograph 3  
Lung: Bronchiolar-alveolar adenoma (Arrows)  
Mouse, Female, 200 ppm, Animal No. 0458-2301 (H&E)



Photograph 4  
Kidney: Basophilic change (Arrows), Glomerulus(G)  
Mouse, Male, 200 ppm, Animal No. 0458-1303 (H&E)



Photograph 5  
Nasal cavity: Atrophy of olfactory epithelium (Arrows)  
Mouse, Male, 200 ppm, Animal No. 0458-1338 (H&E)



Photograph 6  
Nasal cavity: Respiratory metaplasia of olfactory epithelium (Arrows), Respiratory metaplasia of submucosal gland (Arrow heads)  
Mouse, Female, 200 ppm, Animal No. 0458-2315 (H&E)