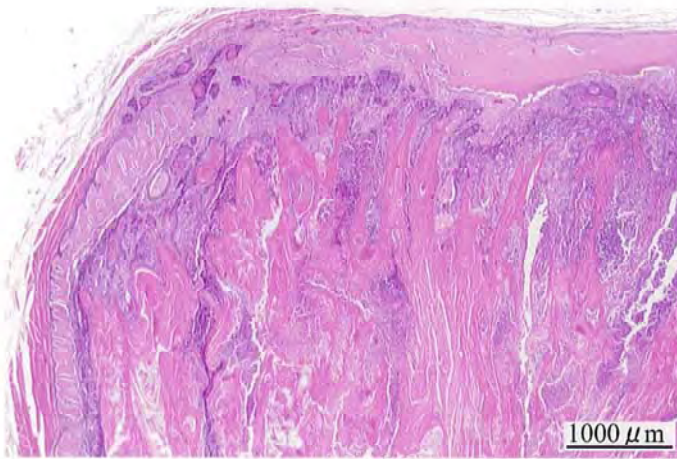


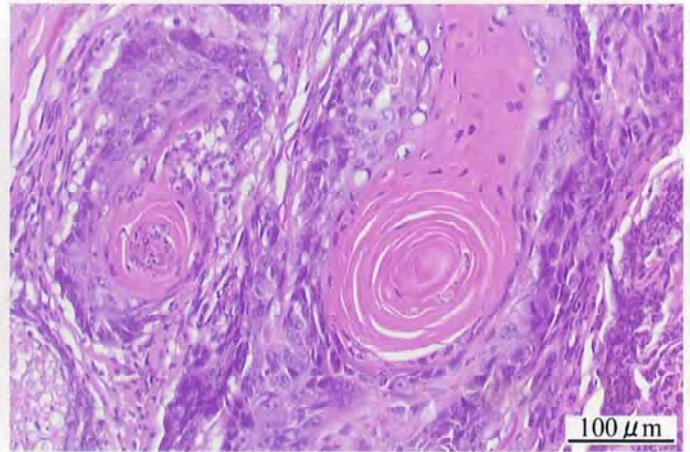
ブチル 2,3-エポキシプロピル エーテルのラット  
を用いた吸入によるがん原性試験報告書

試験番号 : 0437

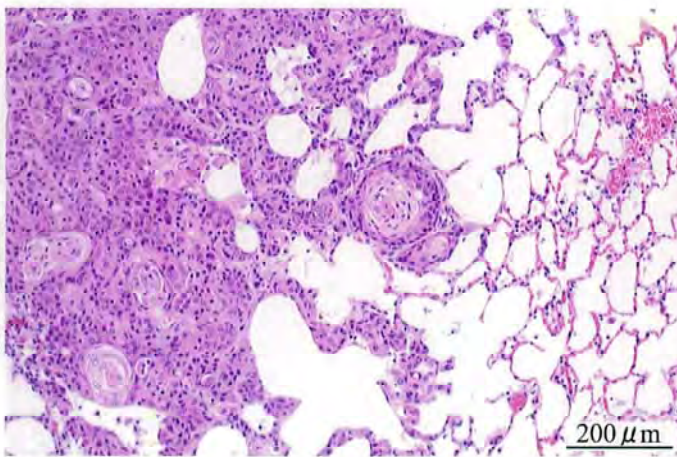
# PHOTOGRAPHS



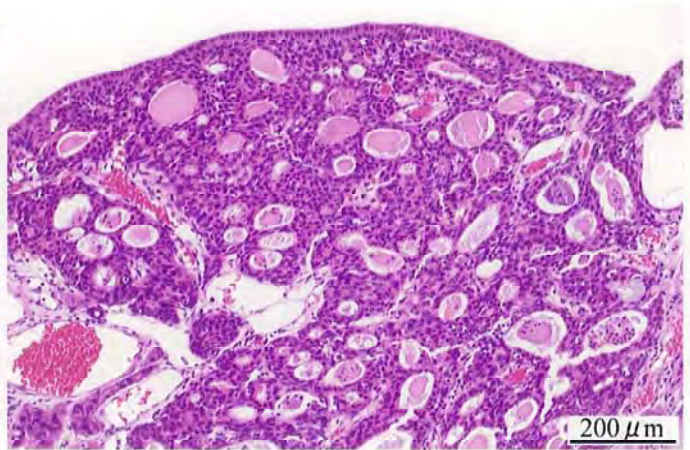
Photograph 1  
Nasal cavity: Squamous cell carcinoma  
Rat, Male, 90 ppm, Animal No. 0437-1322 (H&E)



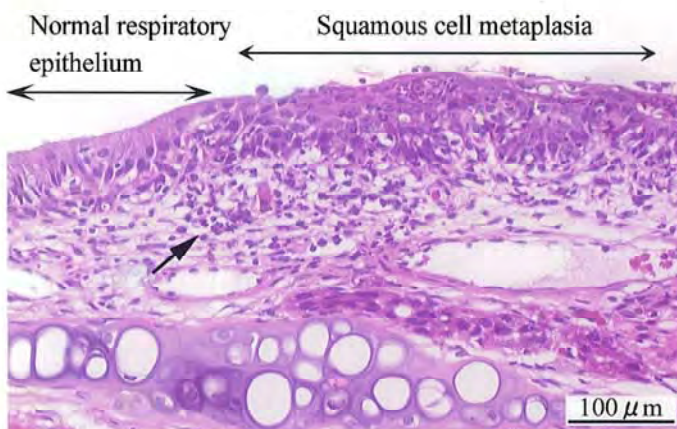
Photograph 2  
Nasal cavity: Squamous cell carcinoma  
Higher magnification of photograph 1.  
Rat, Male, 90 ppm, Animal No. 0437-1322 (H&E)



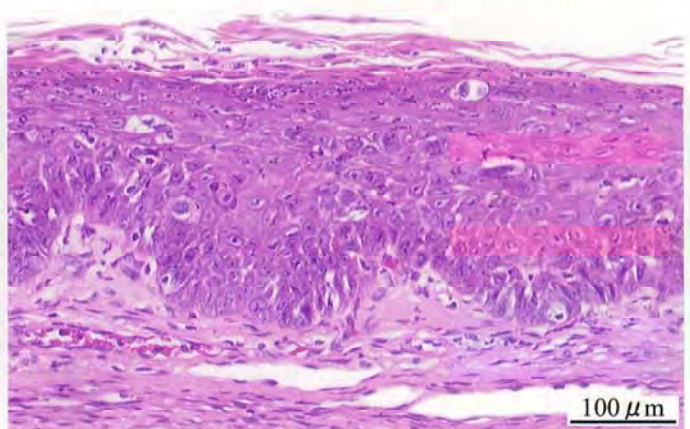
Photograph 3  
Lung: Metastasis of nasal cavity tumor  
(squamous cell carcinoma)  
Rat, Male, 90 ppm, Animal No. 0437-1301 (H&E)



Photograph 4  
Nasal cavity: Adenoma  
Rat, Male, 30 ppm, Animal No. 0437-1210 (H&E)

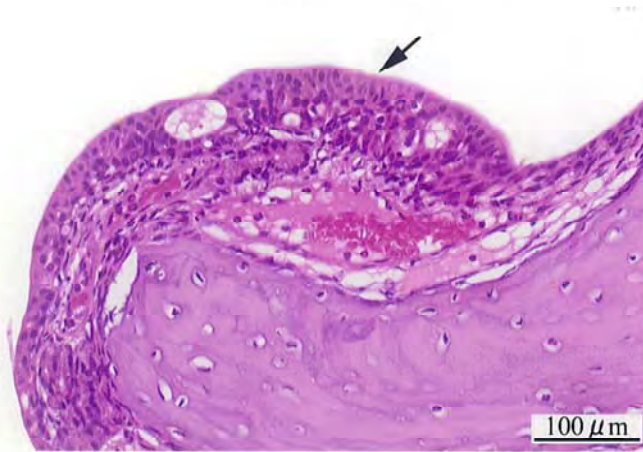


Photograph 5  
Nasal cavity (respiratory epithelium): Squamous cell metaplasia and inflammation (Arrow)  
Rat, Male, 90 ppm, Animal No. 0437-1336 (H&E)

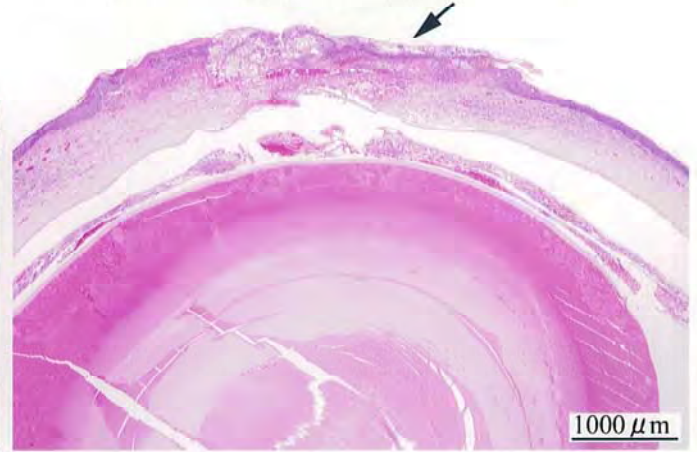


Photograph 6  
Nasal cavity (respiratory epithelium): Squamous cell metaplasia with hyperplasia  
Rat, Male, 90 ppm, Animal No. 0437-1307 (H&E)





Photograph 7  
Nasal cavity (transitional epithelium): Hyperplasia (Arrow)  
Rat, Male, 30 ppm, Animal No. 0437-1246 (H&E)



Photograph 8  
Eye: Keratitis (Arrow)  
Rat, Male, 90 ppm, Animal No. 0437-1343 (H&E)