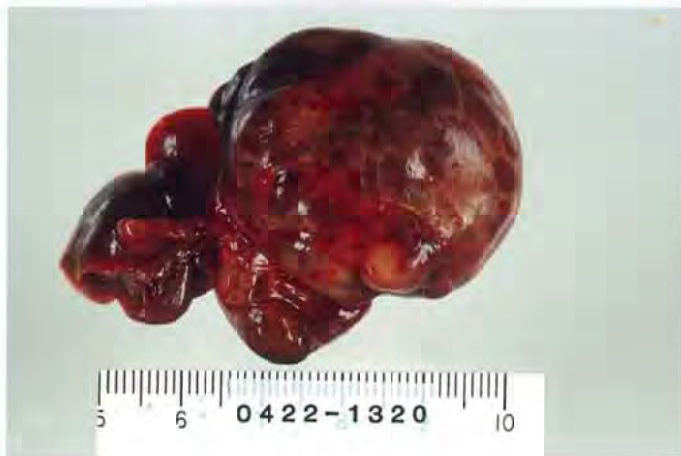

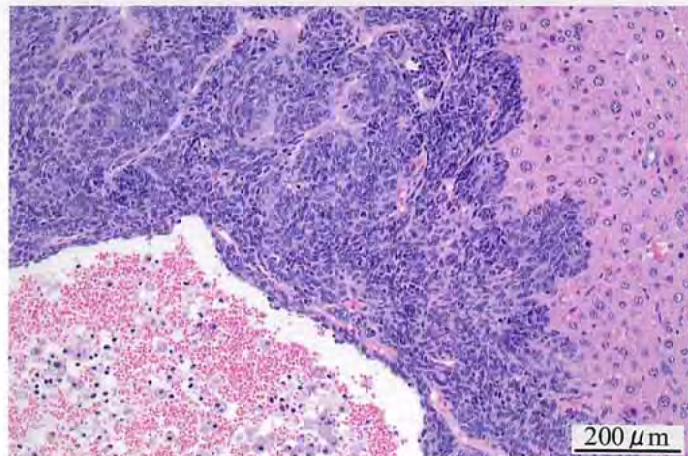
2,4-ジクロロ-1-ニトロベンゼンのマウスを用いた
経口投与によるがん原性試験(混餌試験)報告書

試験番号：0422

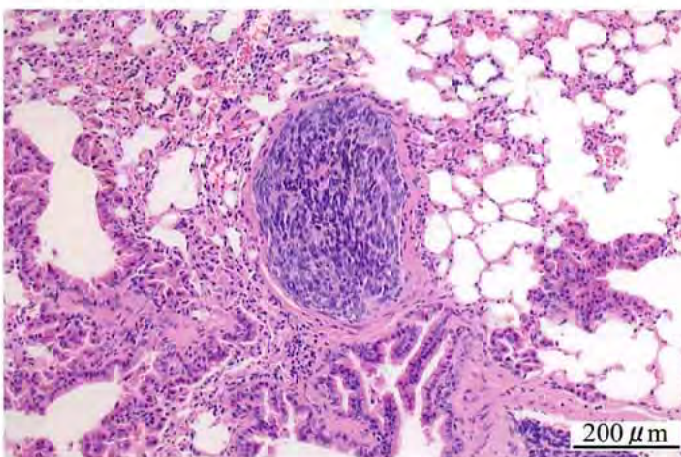
PHOTOGRAPHS



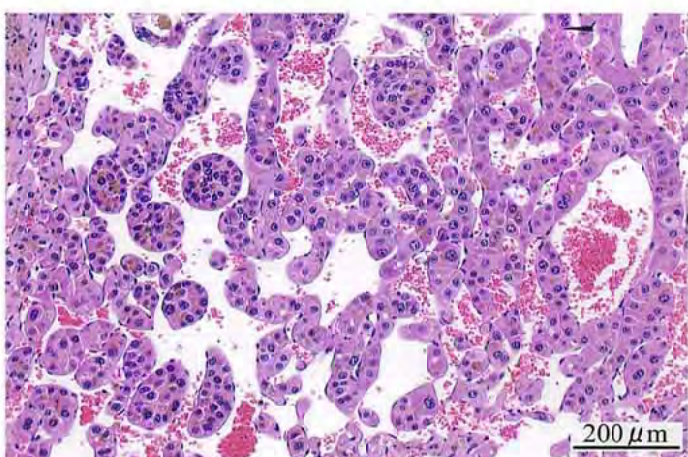
Photograph 1
Liver: Nodule (Hepatoblastoma)
Mouse, Male, 3000 ppm, Animal No. 0422-1320



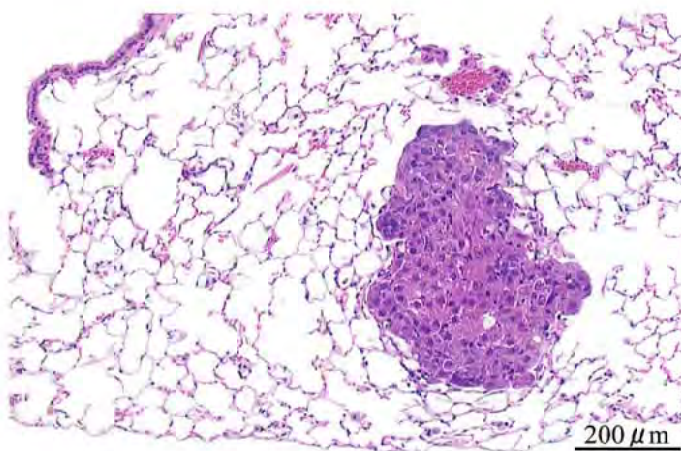
Photograph 2
Liver: Hepatoblastoma
Mouse, Male, 3000ppm, Animal No. 0422-1302 (H&E)



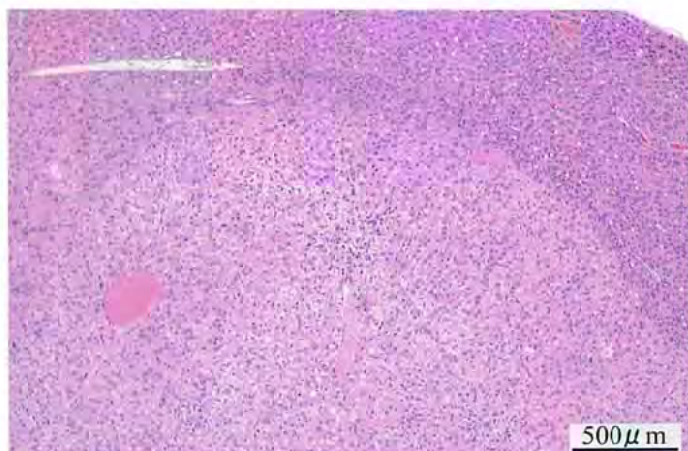
Photograph 3
Lung: Metastasis of hepatoblastoma
Mouse, Male, 3000 ppm, Animal No. 0422-1302 (H&E)



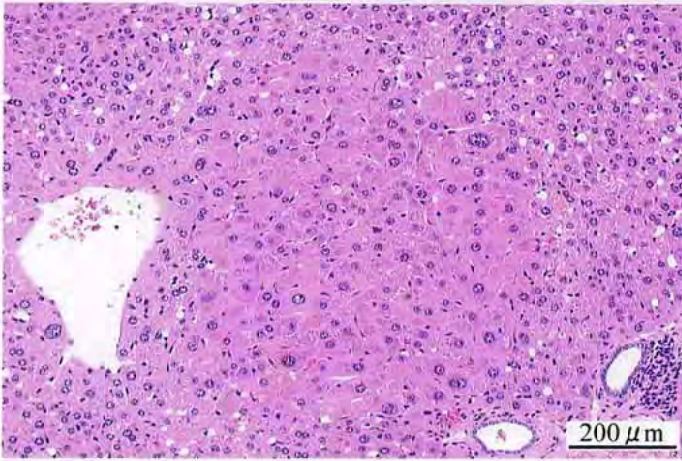
Photograph 4
Liver: Hepatocellular carcinoma
Mouse, Female, 6000 ppm, Animal No. 0422-2324 (H&E)



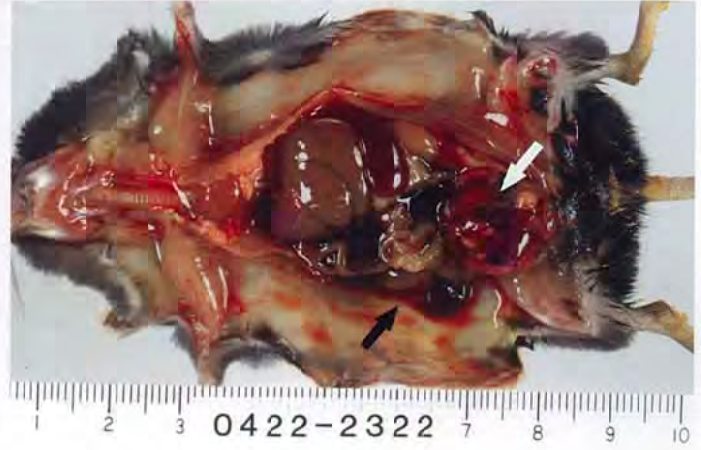Photograph 5
Lung: Metastasis of hepatocellular carcinoma
Mouse, Female, 6000 ppm, Animal No. 0422-2324 (H&E)



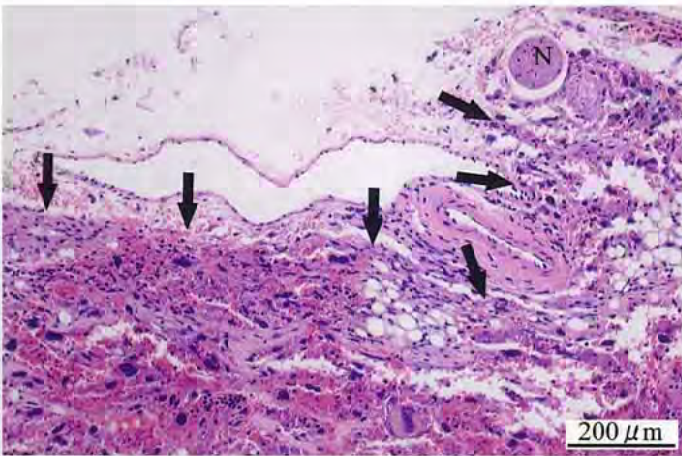
Photograph 6
Liver: Hepatocellular adenoma
Mouse, Male, 750 ppm, Animal No. 0422-1129 (H&E)



Photograph 7
Liver: Acidophilic cell focus
Mouse, Female, 6000 ppm, Animal No. 0422-2324 (H&E)



Photograph 8
Peritoneum: Nodule
Mouse, Female, 6000 ppm, Animal No. 0422-2322
Note a reddish nodule in the pelvic cavity (open arrow) and hemorrhagic fluid (filled arrow).



Photograph 9
Peritoneum: Hemangiosarcoma (Arrows)
Mouse, Female, 6000 ppm, Animal No. 0422-2322 (H&E)
N: Nerve bundle