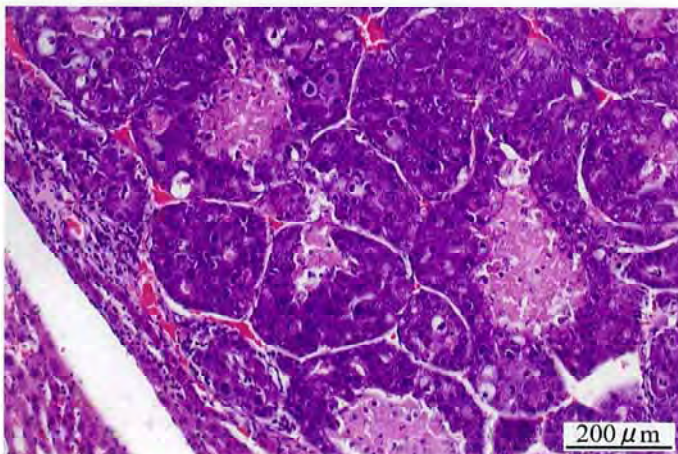


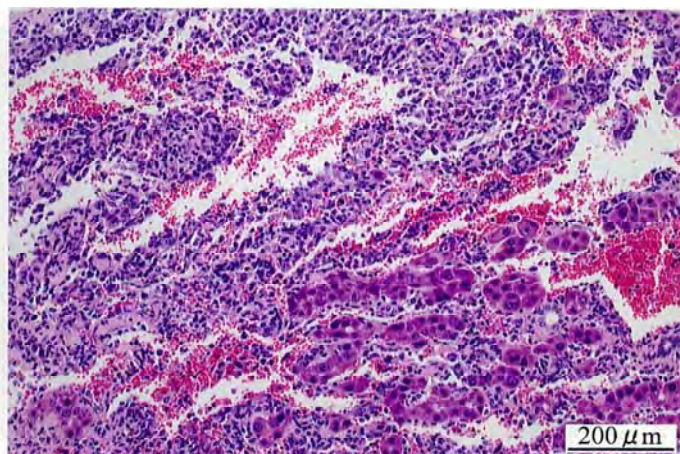
1-ブロモ-3-クロロプロバンのラットを用いた
吸入によるがん原性試験報告書

試験番号：0417

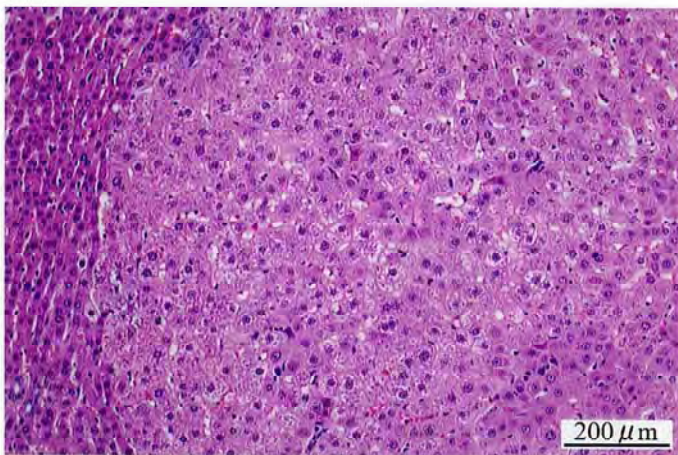
PHOTOGRAPHS



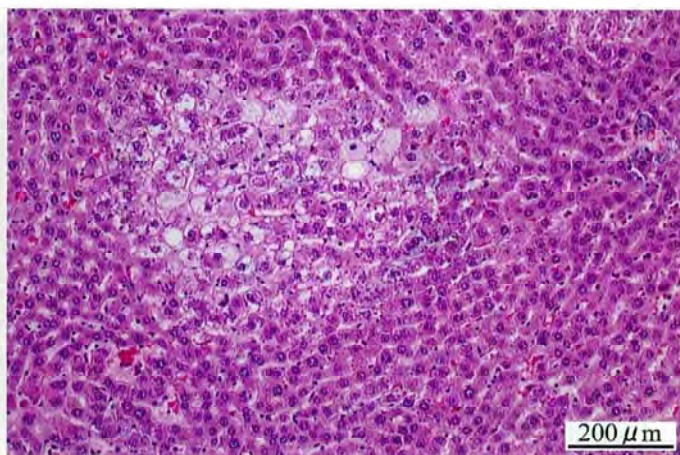
Photograph 1
Liver: Hepatocellular carcinoma
Rat, Female, 400 ppm, Animal No. 0417-2318 (H&E)



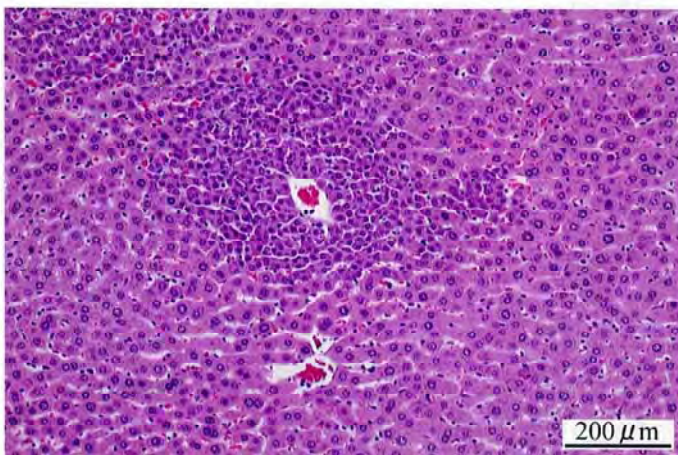
Photograph 2
Liver: Hemangiosarcoma
Rat, Female, 400 ppm, Animal No. 0417-2341 (H&E)



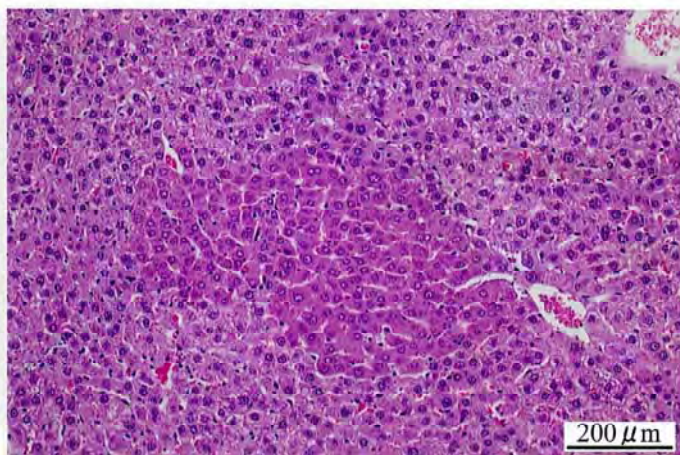
Photograph 3
Liver: Hepatocellular adenoma
Rat, Female, 400 ppm, Animal No. 0417-2316 (H&E)



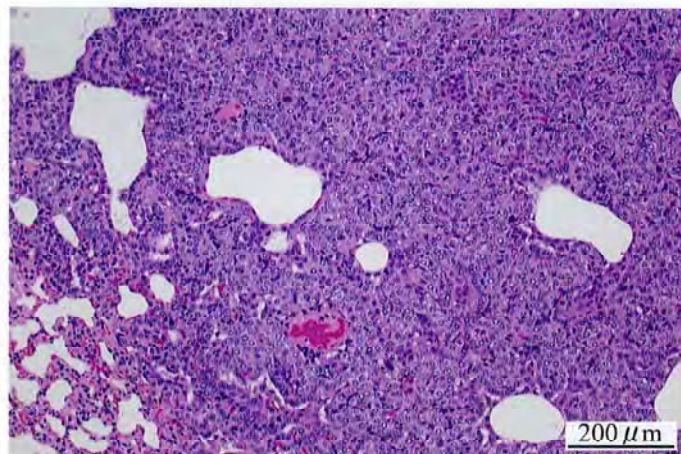
Photograph 4
Liver: Clear cell focus
Rat, Female, 400 ppm, Animal No. 0417-2332 (H&E)



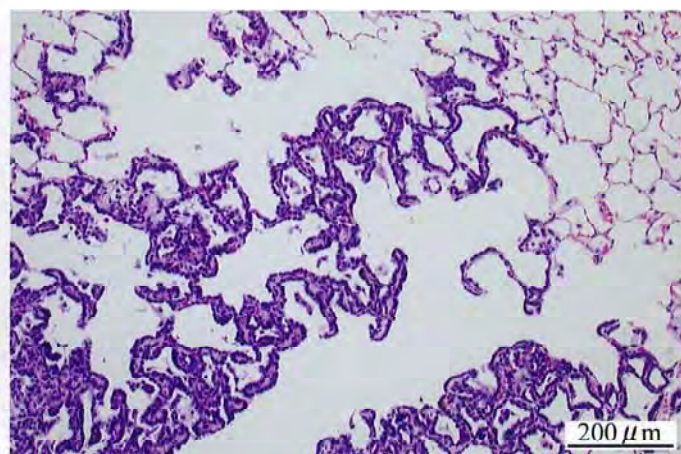
Photograph 5
Liver: Basophilic cell focus
Rat, Male, 400 ppm, Animal No. 0417-1304 (H&E)



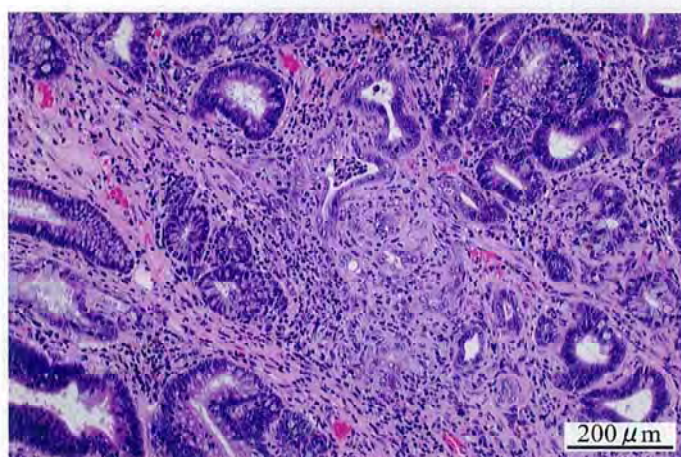
Photograph 6
Liver: Acidophilic cell focus
Rat, Female, 400 ppm, Animal No. 0417-2304 (H&E)



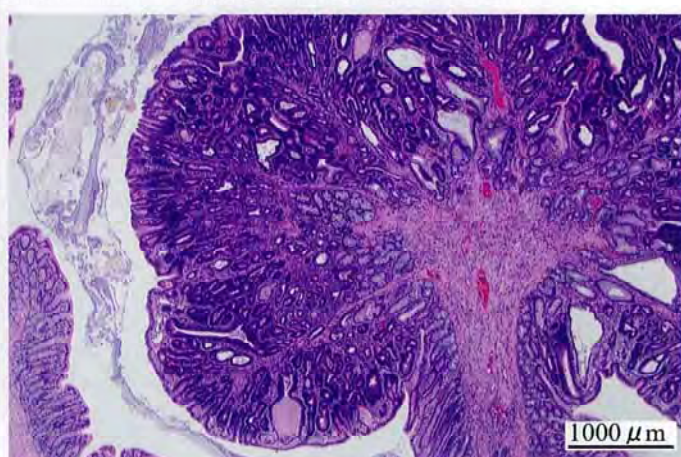
Photograph 7
Lung: Bronchiolar-alveolar adenoma
Rat, Male, 400 ppm, Animal No. 0417-1344 (H&E)



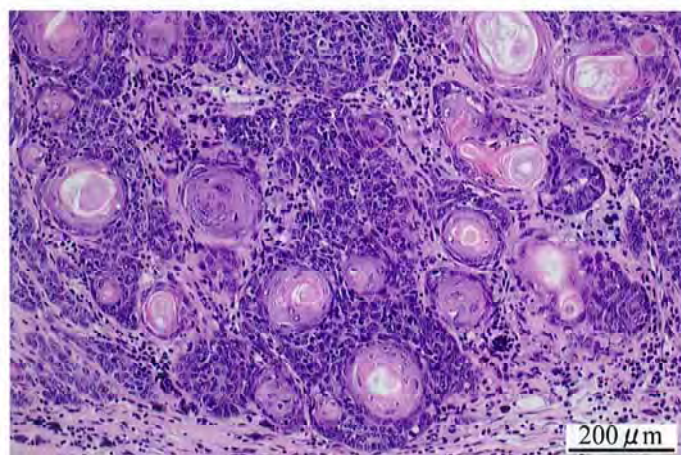
Photograph 8
Lung: Bronchiolar-alveolar cell hyperplasia
Rat, Male, 400 ppm, Animal No. 0417-1346 (H&E)



Photograph 9
Large intestine: Adenocarcinoma
Rat, Male, 400 ppm, Animal No. 0417-1318 (H&E)



Photograph 10
Large intestine: Adenoma
Rat, Male, 400 ppm, Animal No. 0417-1344 (H&E)



Photograph 11
Skin/appendage: Trichoepithelioma
Rat, Male, 400 ppm, Animal No. 0417-1349 (H&E)