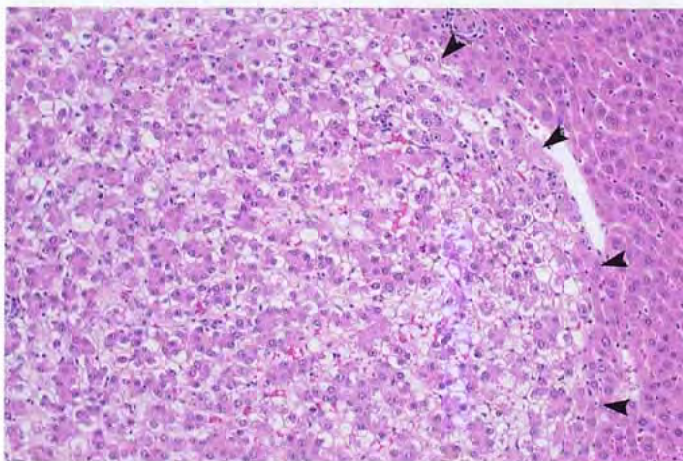


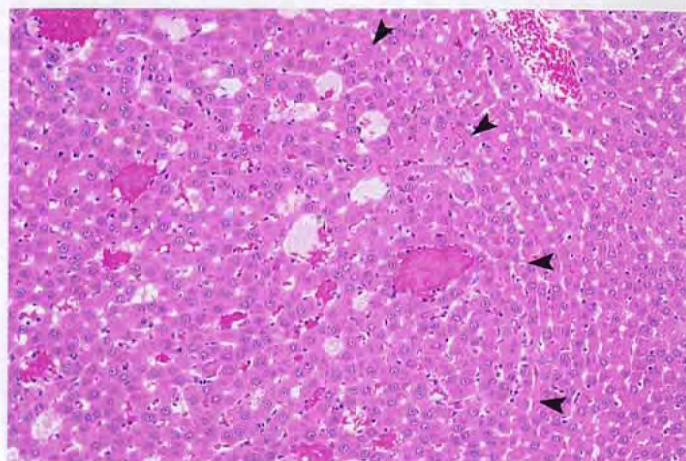
シクロヘキセンのラットを用いた
吸入によるがん原性試験報告書

試験番号：0399

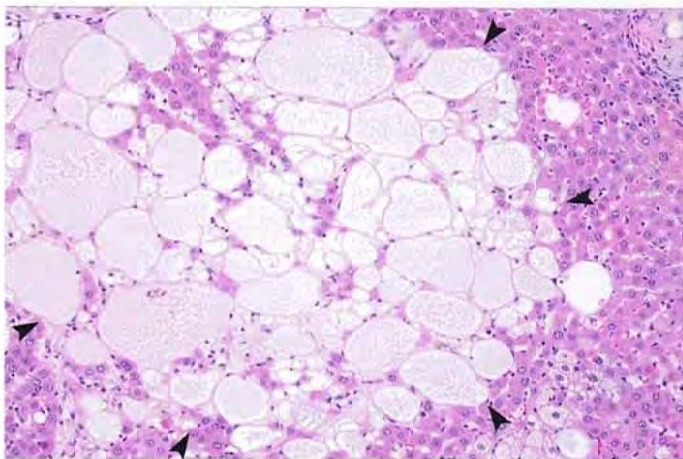
PHOTOGRAPHS



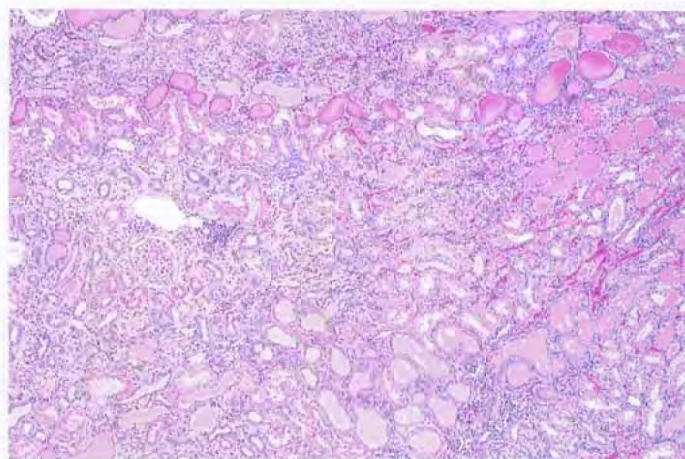
Photograph 1
Liver: Hepatocellular adenoma (arrow heads).
Rat, Male, 2400ppm, Animal No. 0399-1318 (H&E)



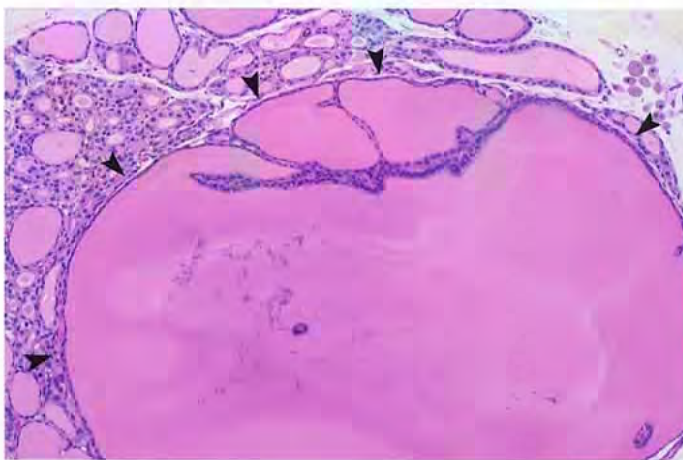
Photograph 2
Liver: Acidophilic cell focus (arrow heads).
Rat, Male, 2400ppm, Animal No. 0399-1315 (H&E)



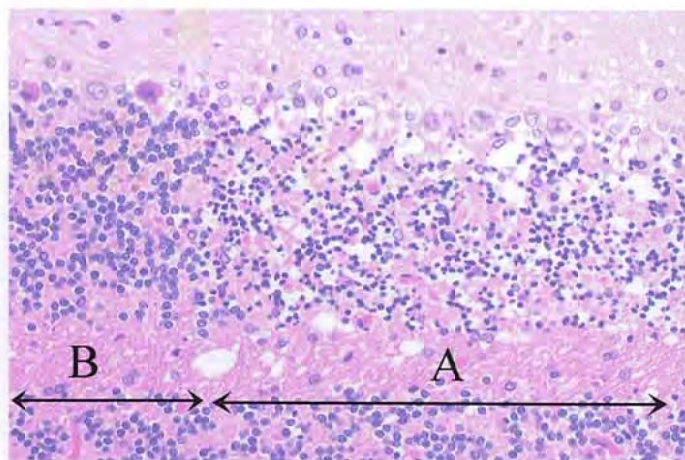
Photograph 3
Liver: Spongiosis hepatis (arrow heads).
Rat, Male, 2400ppm, Animal No. 0399-1317 (H&E)



Photograph 4
Kidney: Chronic nephropathy (severe).
Rat, Male, 2400ppm, Animal No. 0399-1348 (H&E)



Photograph 5
Thyroid: Focal follicular cell hyperplasia (arrow heads).
Rat, Male, 2400ppm, Animal No. 0399-1336 (H&E)



Photograph 6
Brain: Degeneration of granular cells in the granular layer of the cerebellum (A). Normal granular layer (B).
Rat, Female, 2400ppm, Animal No. 0399-2339 (H&E)