

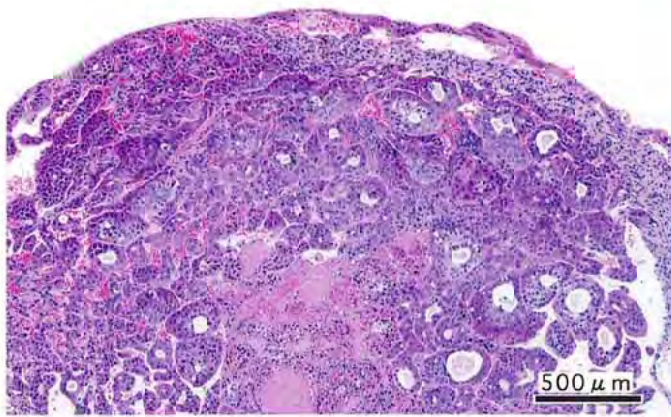
o-フェニレンジアミン二塩酸塩のマウスを用いた  
経口投与によるがん原性試験(混水試験)報告書

試験番号：0372

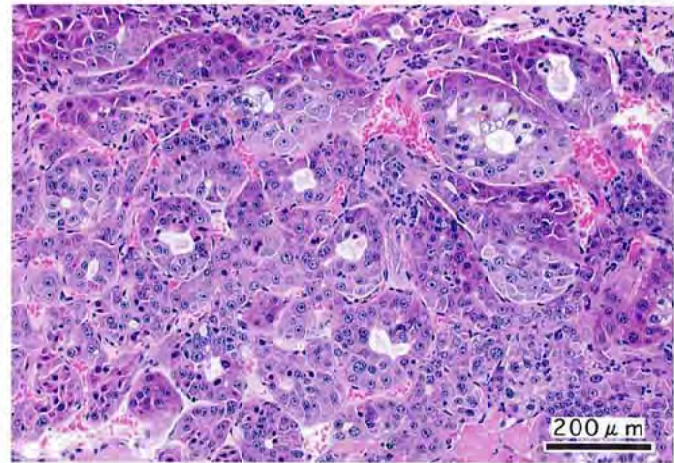
PHOTOGRAPHS

## PHOTOGRAPHS

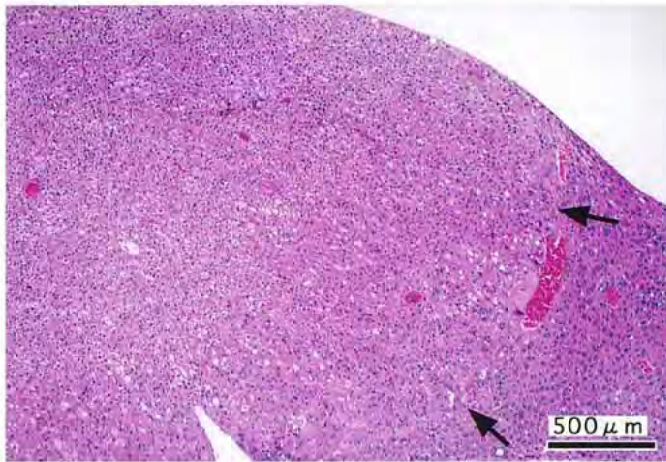
- PHOTOGRAPH 1 LIVER: HEPATOCELLULAR CARCINOMA,  
MOUSE, FEMALE, 4000 ppm, ANIMAL NO. 0372-2334 (H&E)
- PHOTOGRAPH 2 LIVER: HEPATOCELLULAR CARCINOMA,  
HIGH MAGNIFICATION OF PHOTOGRAPH 1
- PHOTOGRAPH 3 LIVER: HEPATOCELLULAR ADENOMA, (ARROW)  
MOUSE, FEMALE, 2000 ppm, ANIMAL NO. 0372-2201 (H&E)
- PHOTOGRAPH 4 LIVER: BASOPHILIC CELL FOCUS, (ARROW)  
MOUSE, MALE, 2000 ppm, ANIMAL NO. 0372-1309 (H&E)
- PHOTOGRAPH 5 LIVER: ACIDOPHILIC CELL FOCUS, (ARROW)  
MOUSE, FEMALE, 4000 ppm, ANIMAL NO. 0372-2323 (H&E)
- PHOTOGRAPH 6 LIVER: CLEAR CELL FOCUS, (ARROW)  
MOUSE, FEMALE, 4000 ppm, ANIMAL NO. 0372-2349 (H&E)
- PHOTOGRAPH 7 GALL BLADDER: PAPILLARY ADENOMA,  
(ARROW: GALL BLADDER, ARROWHEAD: PAPILLARY ADENOMA )  
MOUSE, MALE, 2000 ppm, ANIMAL NO. 0372-1334 (H&E)
- PHOTOGRAPH 8 GALL BLADDER: HYPERPLASIA, (ARROW)  
MOUSE, MALE, 2000 ppm, ANIMAL NO. 0372-1331 (H&E)
- PHOTOGRAPH 9 NASAL CAVITY: EOSINOPHILIC CHANGE OF THE OLFATORY  
EPITHELIUM, (ARROW)  
MOUSE, FEMALE, 4000 ppm, ANIMAL NO. 0372-2302 (H&E)
- PHOTOGRAPH 10 NASAL CAVITY: EOSINOPHILIC CHANGE OF THE RESPIRATORY  
EPITHELIUM, (ARROW)  
MOUSE, FEMALE, 4000 ppm, ANIMAL NO. 0372-2320 (H&E)
- PHOTOGRAPH 11 NASAL CAVITY: EOSINOPHILIC CHANGE OF THE GLAND, (ARROW)  
MOUSE, FEMALE, 4000 ppm, ANIMAL NO. 0372-2320 (H&E)
- PHOTOGRAPH 12 KIDNEY: INFLAMMATORY POLYP,(ARROW)  
MOUSE, MALE, 2000 ppm, ANIMAL NO. 0372-1302 (H&E)



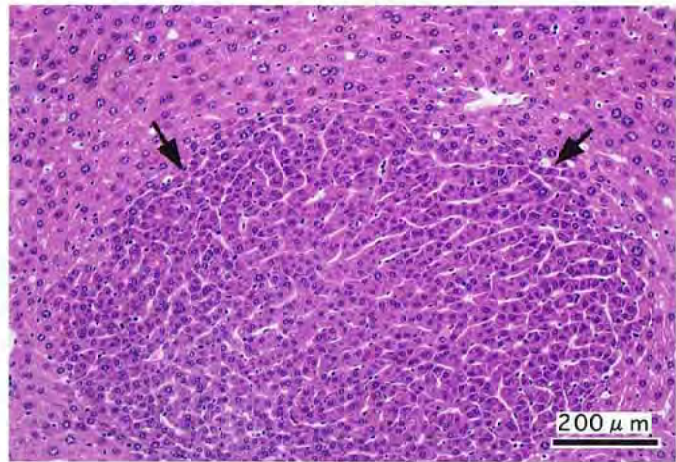
PHOTOGRAPH 1



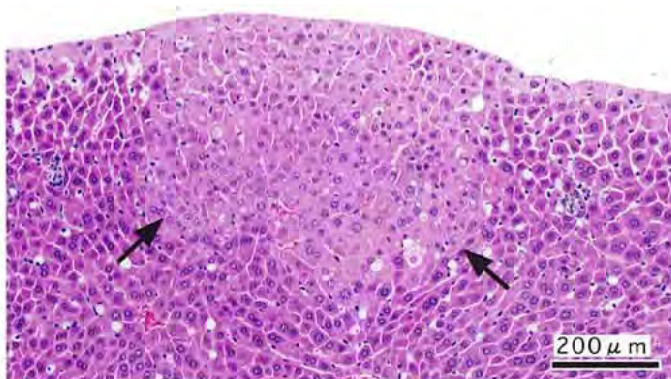
PHOTOGRAPH 2



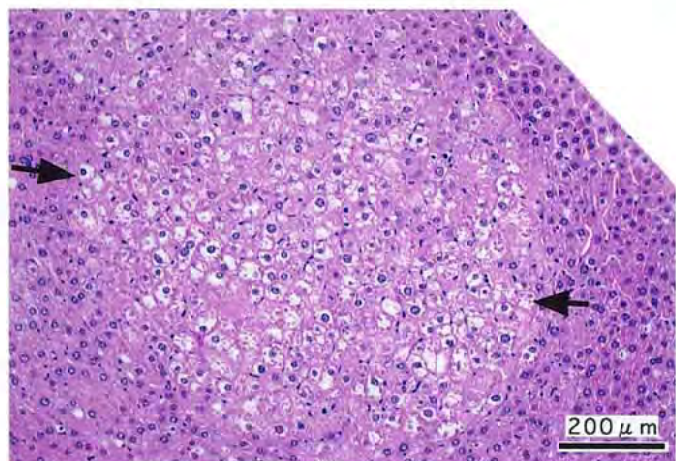
PHOTOGRAPH 3



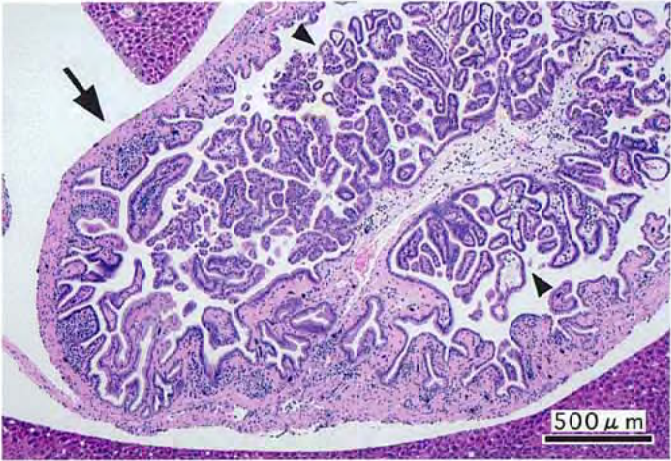PHOTOGRAPH 4



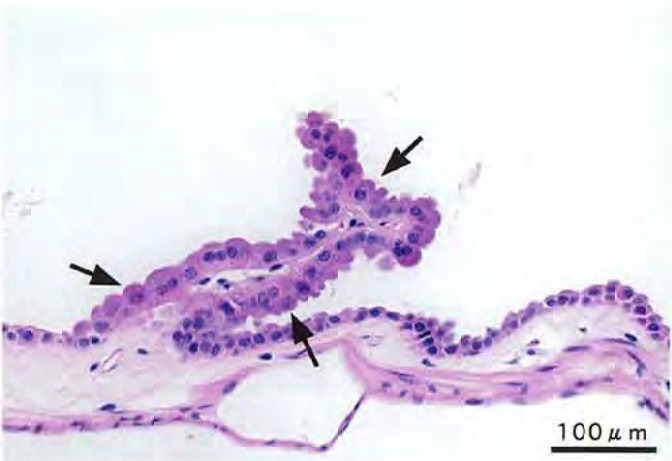PHOTOGRAPH 5



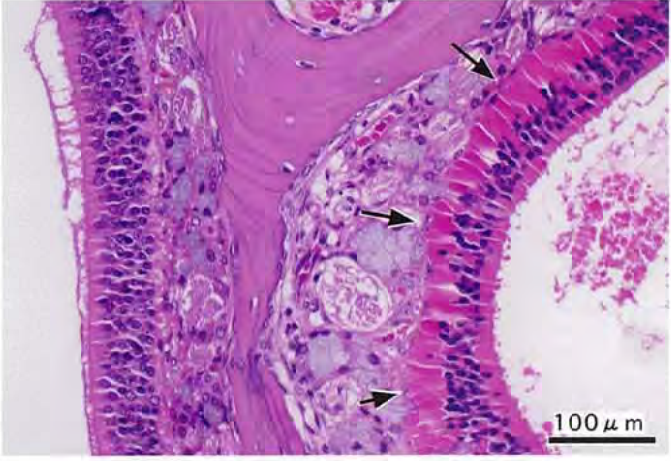
PHOTOGRAPH 6



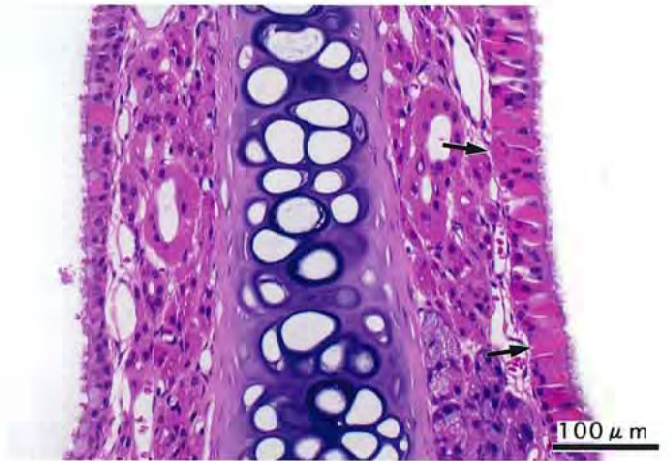
PHOTOGRAPH 7



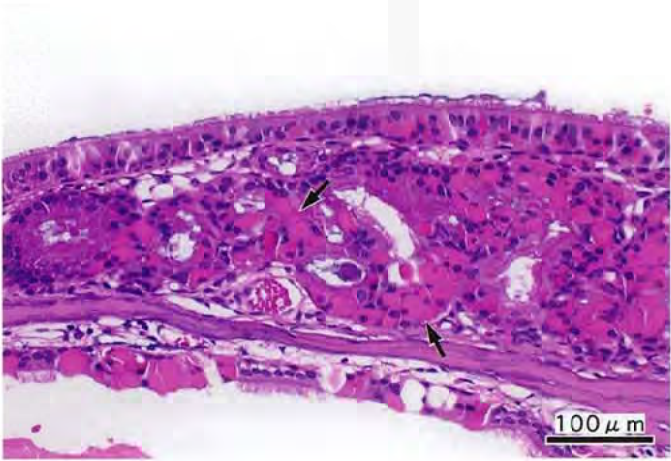
PHOTOGRAPH 8



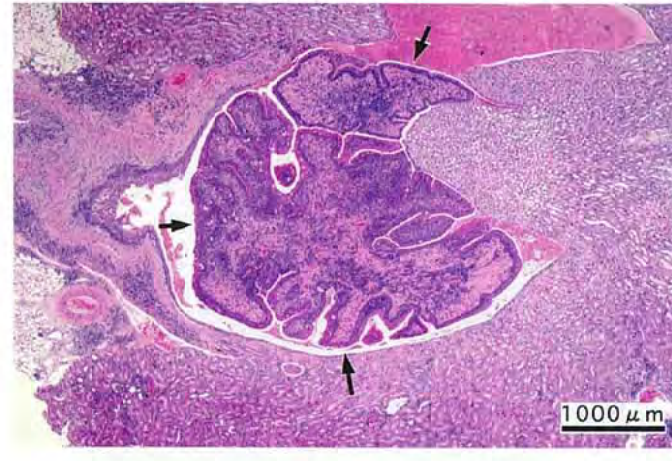
PHOTOGRAPH 9



PHOTOGRAPH 10



PHOTOGRAPH 11



PHOTOGRAPH 12