

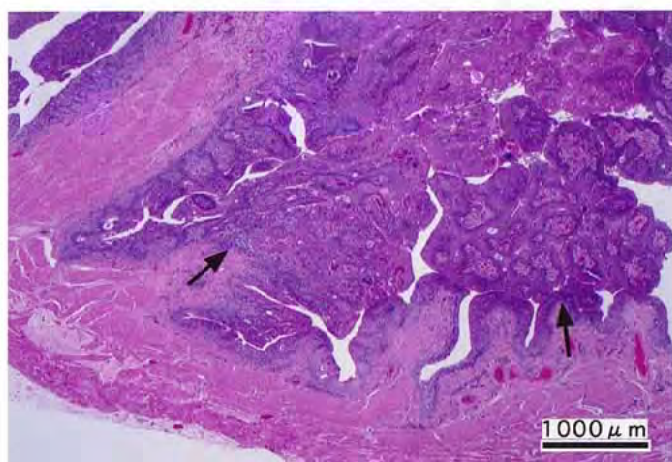
アリルクロリドのラットを用いた  
吸入によるがん原性試験報告書

試験番号 : 0365

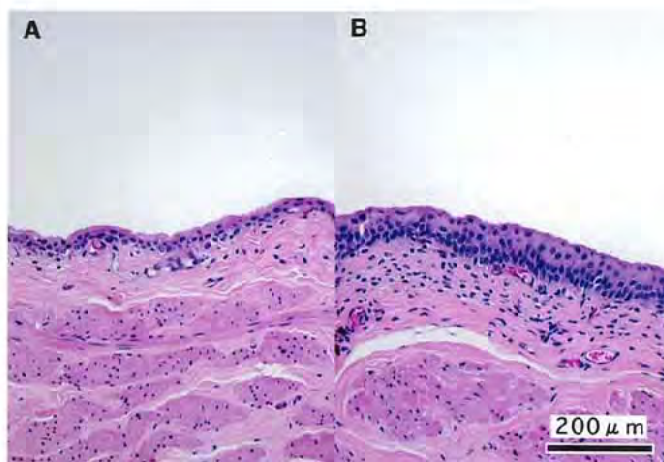
**PHOTOGRAPHS**

## PHOTOGRAPHS

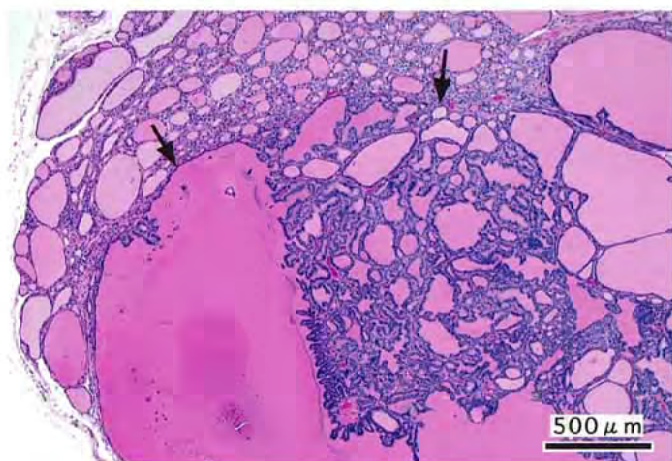
- PHOTOGRAPH 1 URINARY BLADDER  
TRANSITIONAL CELL CARCINOMA (ARROW)  
RAT, MALE, 100ppm, ANIMAL No. 0365-1329( H&E )
- PHOTOGRAPH 2 URINARY BLADDER : TRANSITIONAL EPITHELIUM  
A: NORMAL EPITHELIUM  
RAT, MALE, CONTROL, ANIMAL No. 0365-1002 ( H&E )  
B: SIMPLE HYPERPLASIA (ARROW)  
RAT, MALE, 100ppm, ANIMAL No. 0365-1328 ( H&E )
- PHOTOGRAPH 3 THYROID  
FOLLICULAR ADENOMA(ARROW)  
RAT, MALE, 100ppm, ANIMAL No. 0365-1334( H&E )
- PHOTOGRAPH 4 KIDNEY  
CRONIC NEPHROPATHY  
RAT, MALE, 50ppm, ANIMAL No. 0365-1216 ( H&E )
- PHOTOGRAPH 5 KIDNEY : PROXIMAL TUBULE  
NUCLEAR ENLARGEMENT (ARROW HEAD)  
EOSINOPHILIC DROPLET: PROXIMAL TUBULE (ARROW)  
RAT, FEMALE, 25ppm, ANIMAL No. 0365-2130 ( H&E )
- PHOTOGRAPH 6 NASAL CAVITY : OLFACTORY EPITHELIUM  
A: NORMAL EPITHELIUM  
RAT, MALE, CONTROL, ANIMAL No. 0365-1001 ( H&E )  
B: EOSINOPHILIC CHANGE (ARROW)  
RAT, MALE, 25ppm, ANIMAL No. 0365-1103 ( H&E )



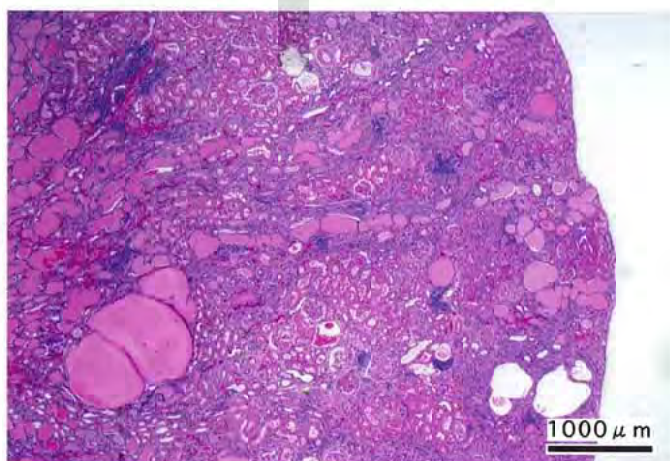
PHOTOGRAPH 1



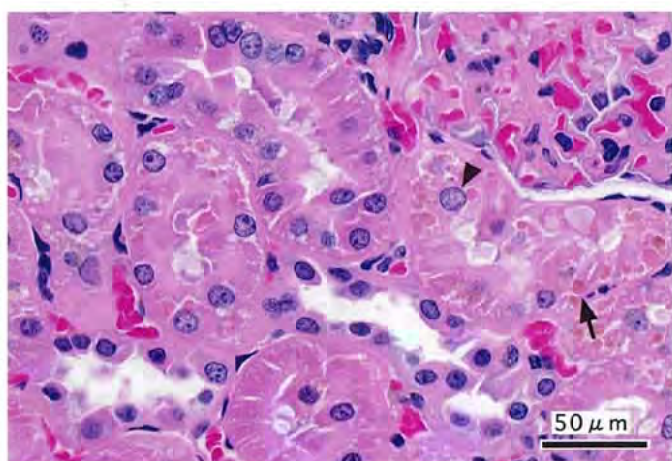
PHOTOGRAPH 2



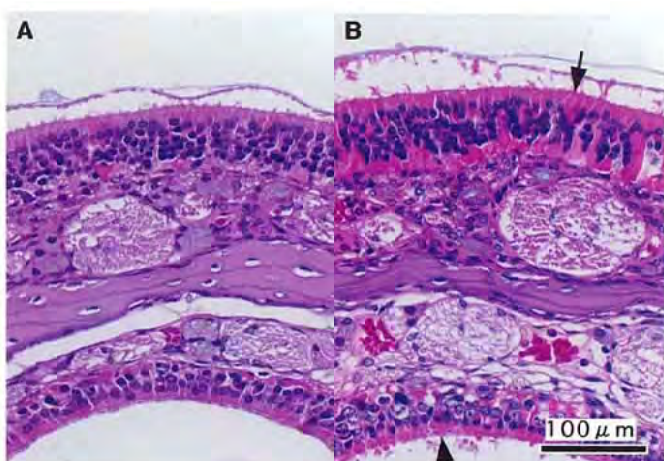
PHOTOGRAPH 3



PHOTOGRAPH 4



PHOTOGRAPH 5



PHOTOGRAPH 6