

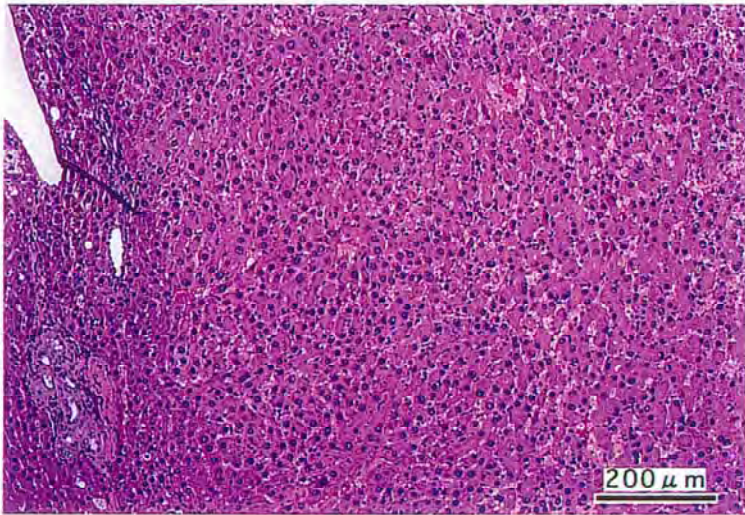
アクリル酸=2-ヒドロキシエチルのラットを用いた  
経口投与によるがん原性試験(混水試験)報告書

試験番号：0347

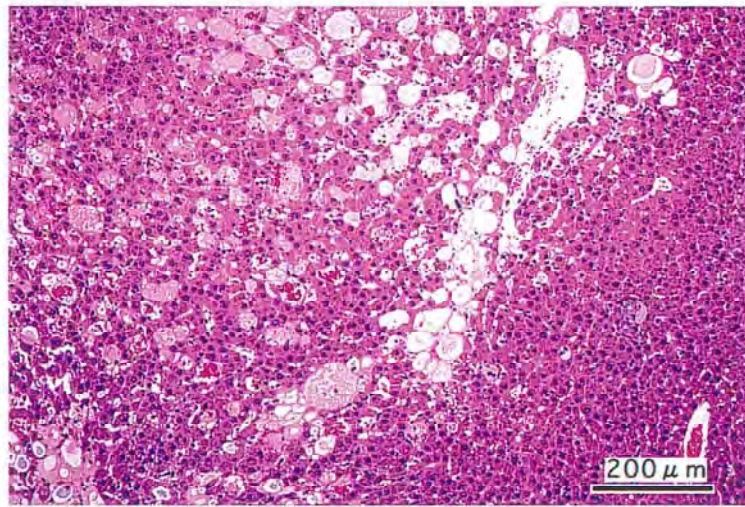
**PHOTOGRAPHS**

## PHOTOGRAPHS

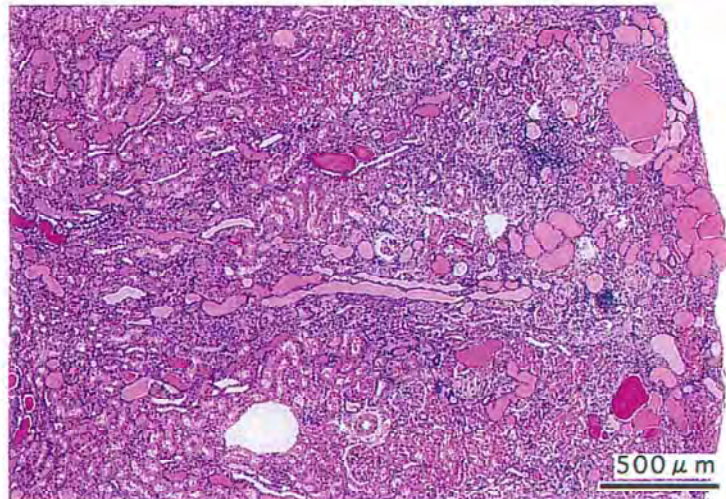
- PHOTOGRAPH 1      LIVER : HEPATOCELLULAR ADENOMA,  
RAT, MALE, 2000 ppm, ANIMAL NO. 0347-1341 (H&E)
- PHOTOGRAPH 2      LIVER : BASOPHILIC CELL FOCUS  
RAT, MALE, 2000 ppm, ANIMAL NO. 0347-1336 (H&E)
- PHOTOGRAPH 3      KIDNEY : CHRONIC NEPHROPATHY,  
RAT, MALE, 2000 ppm, ANIMAL NO. 0347-1319 (H&E)
- PHOTOGRAPH 4      KIDNEY : (A) PAPILLARY NECROSIS  
                          (B) MINERALIZATION : PAPILLA  
                          (C) UROTHELIAL HYPERPLASIA : PELVIS  
RAT, FEMALE, 2000 ppm, ANIMAL NO. 0347-2319 (H&E)



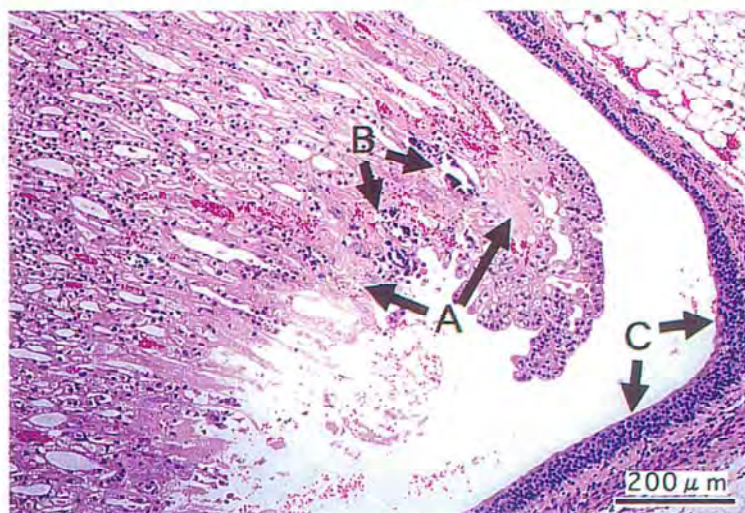
PHOTOGRAPH 1



PHOTOGRAPH 2



PHOTOGRAPH 3



PHOTOGRAPH 4