

グリシドールのマウスを用いた  
吸入によるがん原性試験報告書

試験番号：0343

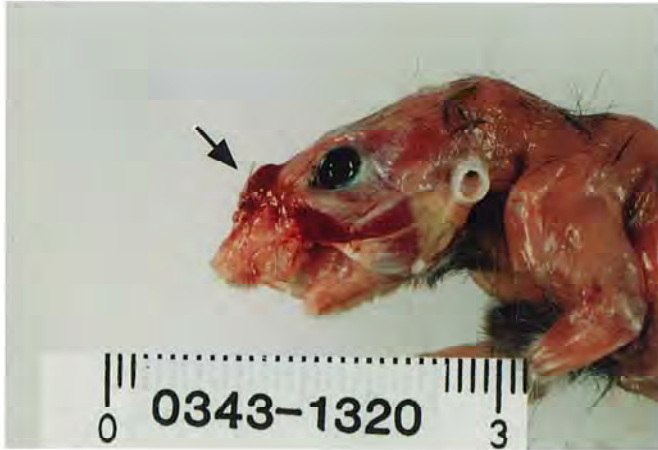PHOTOGRAPHS

## PHOTOGRAPHS

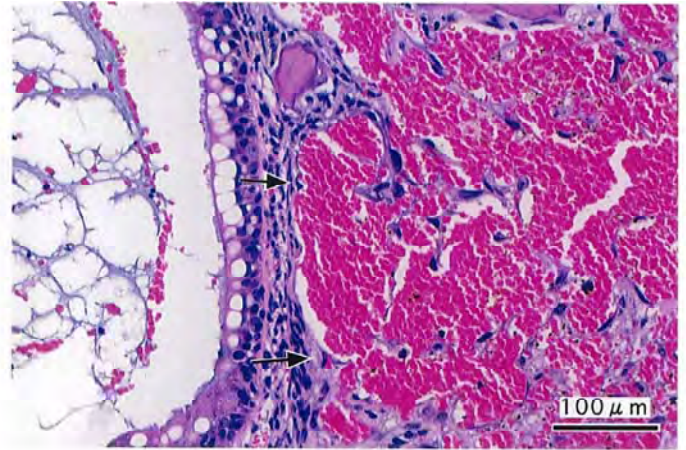
- PHOTOGRAPH 1 NOSE: NODULE (ARROW)  
MOUSE, MALE, 40ppm, ANIMAL No. 0343-1320
- PHOTOGRAPH 2 NASAL CAVITY : HEMANGIOMA (ARROW)  
MOUSE, MALE, 40ppm, ANIMAL No. 0343-1329 ( H&E )
- PHOTOGRAPH 3 NASAL CAVITY : HEMANGIOSARCOMA (ARROW)  
MOUSE, MALE, 40ppm, ANIMAL No. 0343-1335 ( H&E )
- PHOTOGRAPH 4 NASAL CAVITY : HEMANGIOSARCOMA  
HIGHER MAGNIFICATION OF PHOTOGRAPH 3  
MOUSE, MALE, 40ppm, ANIMAL No. 0343-1335 ( H&E )
- PHOTOGRAPH 5 NASAL CAVITY : ADENOMA (ARROW)  
MOUSE, FEMALE, 40ppm, ANIMAL No. 0343-2333 ( H&E )
- PHOTOGRAPH 6 NASAL CAVITY : ADENOCARCINOMA  
MOUSE, FEMALE, 40ppm, ANIMAL No. 0343-2326 ( H&E )
- PHOTOGRAPH 7 NASAL CAVITY : SQUAMOUS CELL CARCINOMA (ARROW)  
MOUSE, MALE, 40ppm, ANIMAL No. 0343-1310 ( H&E )
- PHOTOGRAPH 8 NASAL CAVITY :  
A: NORMAL RESPIRATORY EPITHELIUM (TRANSITIONAL TYPE)  
B: SQUAMOUS METAPLASIA OF THE RESPIRATORY  
EPITHELIUM  
MOUSE, MALE, 13ppm, ANIMAL No. 0343-1231 ( H&E )
- PHOTOGRAPH 9 NASAL CAVITY: SQUAMOUS METAPLASIA WITH ATYPIA OF  
THE RESPIRATORY EPITHELIUM (ARROW)  
MOUSE, MALE, 40ppm, ANIMAL No. 0343-1328 ( H&E )
- PHOTOGRAPH 10 NASAL CAVITY : SQUAMOUS CELL HYPERPLASIA WITH  
ATYPIA (ARROW)  
MOUSE, MALE, 40ppm, ANIMAL No. 0343-1335 ( H&E )
- PHOTOGRAPH 11 NASAL CAVITY : RESPIRATORY METAPLASIA OF THE  
GLAND (ARROW)  
MOUSE, MALE, 40ppm, ANIMAL No. 0343-1301 ( H&E )
- PHOTOGRAPH 12 NASAL CAVITY : RESPIRATORY METAPLASIA OF THE  
OLFACTORY EPITHELIUM (ARROW)  
MOUSE, MALE, 13ppm, ANIMAL No. 0343-1214 ( H&E )

## PHOTOGRAPHS (CONTINUED)

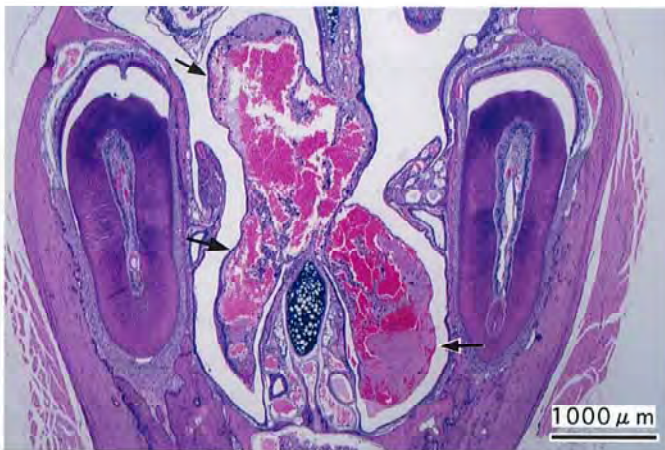- PHOTOGRAPH 13 SUBCUTIS: HISTIOCYTIC SARCOMA (ARROW)  
MOUSE, MALE, 40ppm, ANIMAL No. 0343-1335 ( H&E )
- PHOTOGRAPH 14 PERIPHERAL NERVE: HISTIOCYTIC SARCOMA  
MOUSE, MALE, 40ppm, ANIMAL No. 0343-1348 ( H&E )
- PHOTOGRAPH 15 HARDERIAN GLAND : ADENOMA (ARROW)  
MOUSE, MALE, 40ppm, ANIMAL No. 0343-1306 ( H&E )
- PHOTOGRAPH 16 UTERUS : HISTIOCYTIC SARCOMA  
MOUSE, FEMALE, 40ppm, ANIMAL No. 0343-2339 ( H&E )
- PHOTOGRAPH 17 MAMMARY GLAND : ADENOCARCINOMA  
MOUSE, FEMALE, 40ppm, ANIMAL No. 0343-2333 ( H&E )
- PHOTOGRAPH 18 STOMACH : HYPERPLASIA OF THE FORESTOMACH (ARROW)  
MOUSE, MALE, 40ppm, ANIMAL No. 0343-1349 ( H&E )



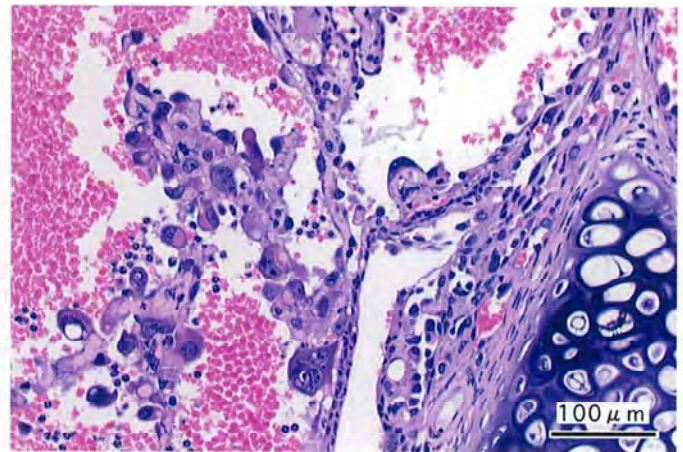
PHOTOGRAPH 1



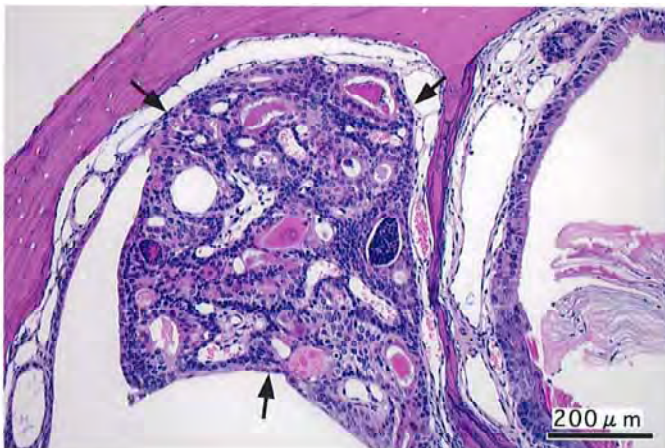
PHOTOGRAPH 2



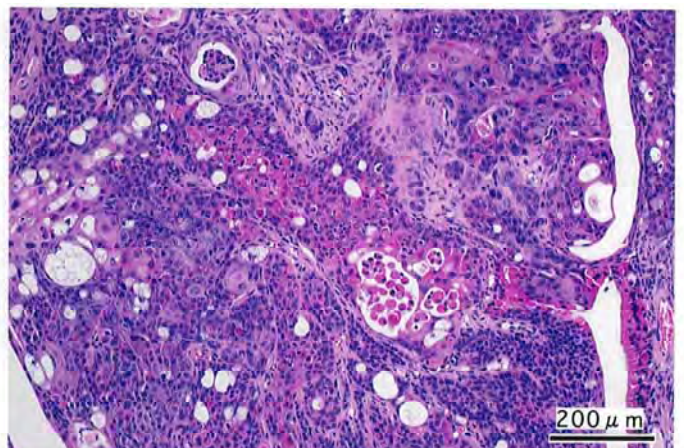
PHOTOGRAPH 3



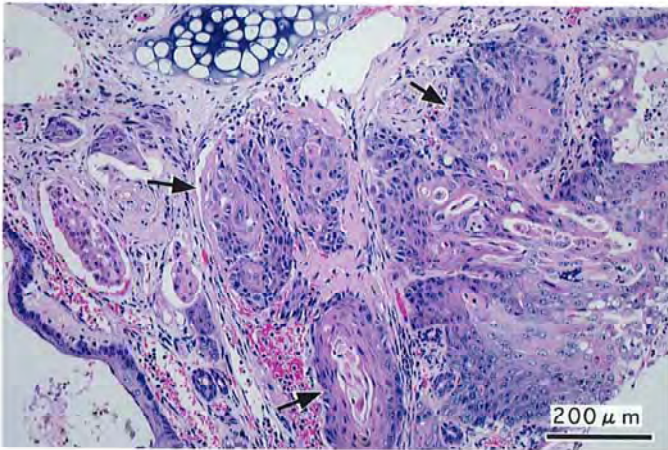
PHOTOGRAPH 4



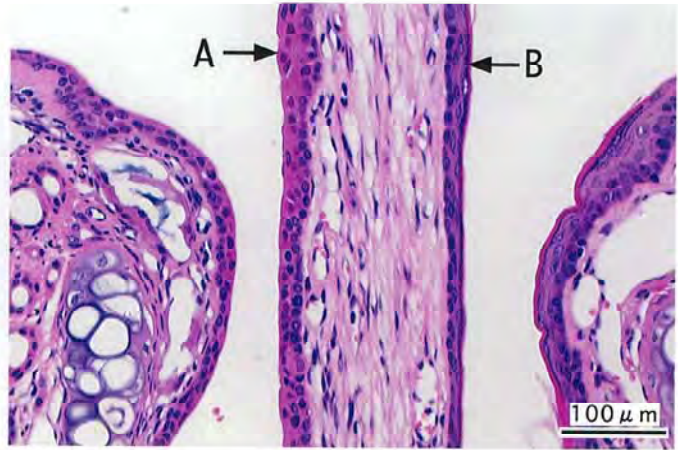
PHOTOGRAPH 5



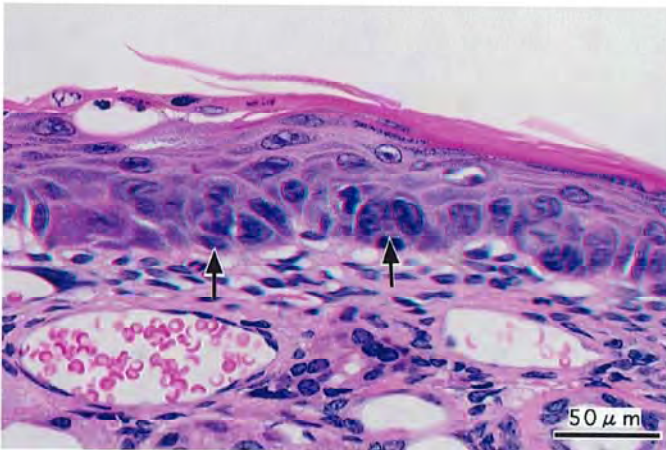
PHOTOGRAPH 6



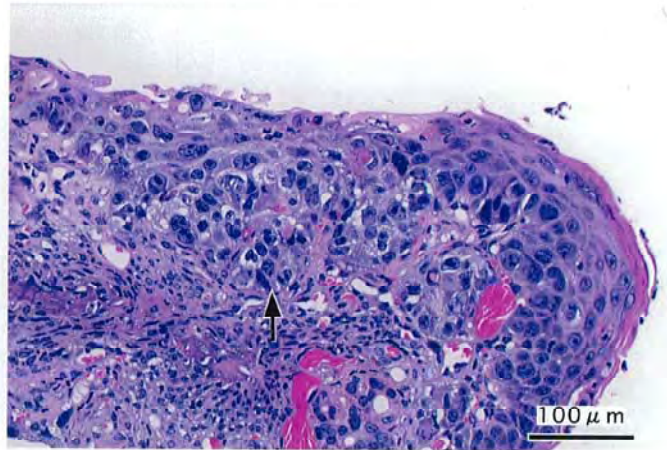
PHOTOGRAPH 7



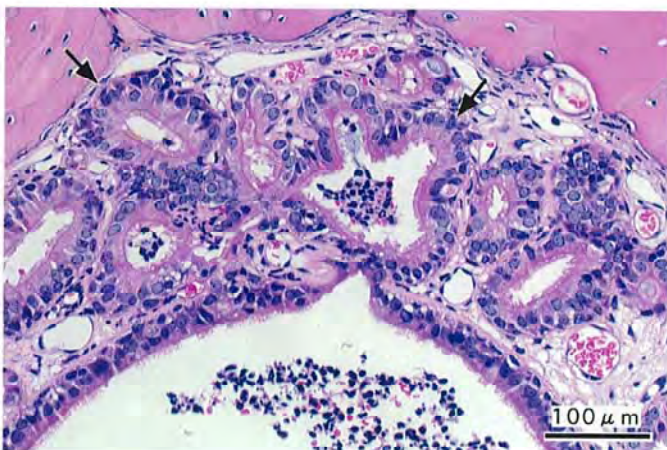
PHOTOGRAPH 8



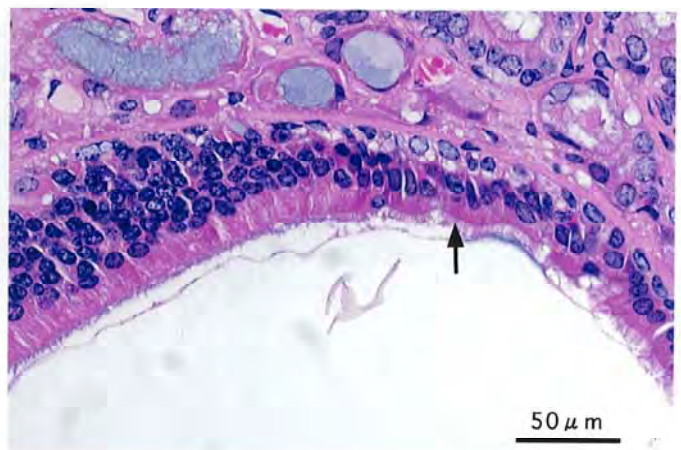
PHOTOGRAPH 9



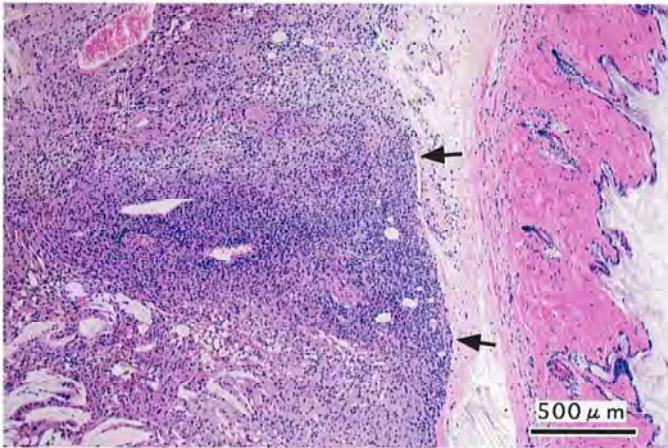
PHOTOGRAPH 10



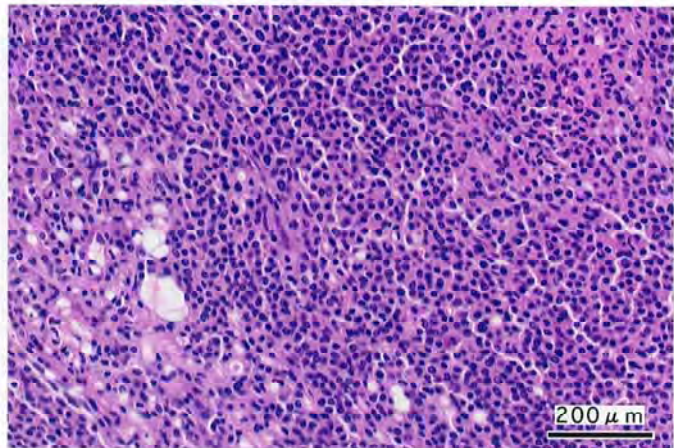
PHOTOGRAPH 11



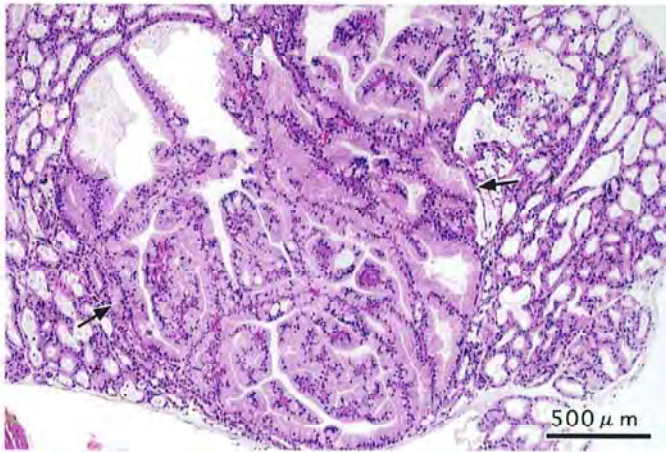
PHOTOGRAPH 12



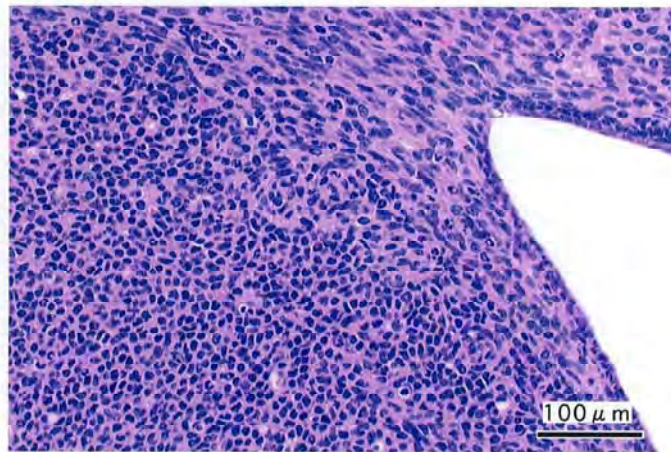
PHOTOGRAPH 13



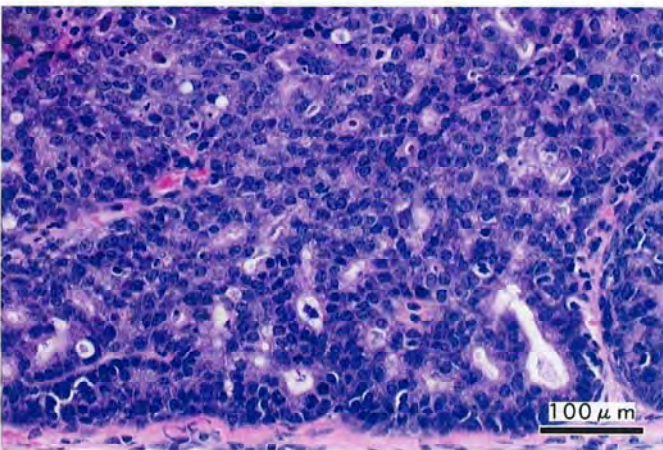
PHOTOGRAPH 14



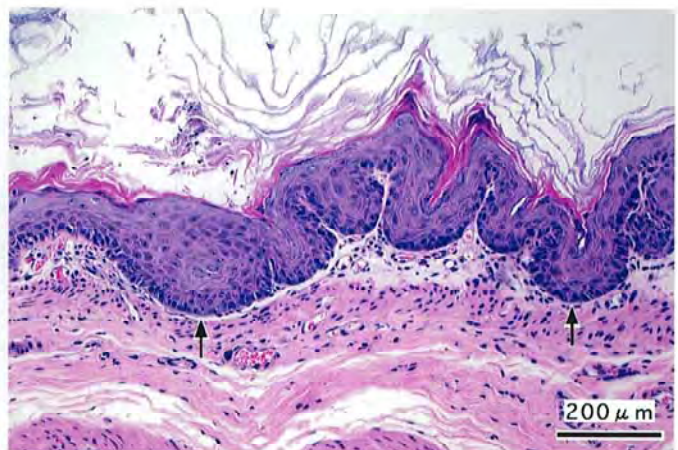
PHOTOGRAPH 15



PHOTOGRAPH 16



PHOTOGRAPH 17



PHOTOGRAPH 18