

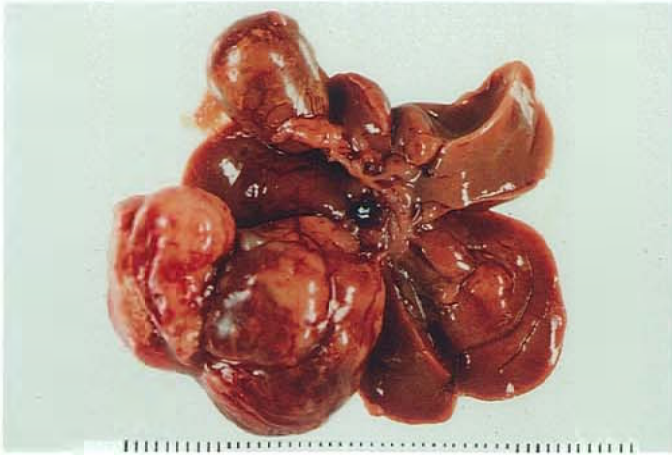
1,4-ジクロロ-2-ニトロベンゼンのマウスを用いた
経口投与によるがん原性試験(混餌試験)報告書

試験番号：0329

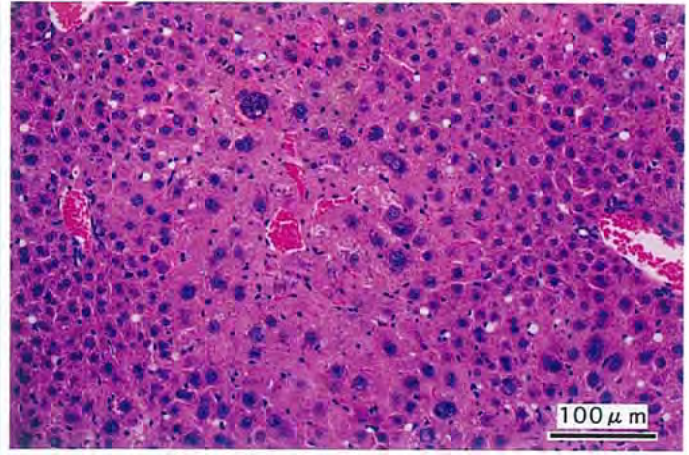
PHOTOGRAPHS

PHOTOGRAPHS

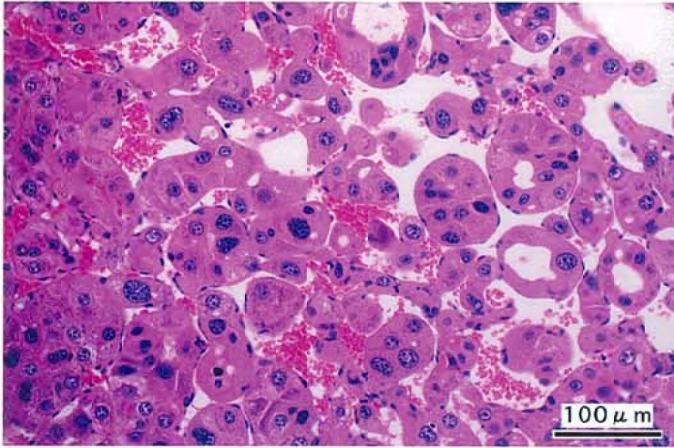
- PHOTOGRAPH 1 LIVER: NODULE,
MOUSE, MALE, 2000 ppm, ANIMAL NO. 0329-1304
- PHOTOGRAPH 2 LIVER: LIVER: HEPATOCELLULAR HYPERTROPHY WITH ATYPIA
OF THE CENTRAL AREA,
MOUSE, MALE, 2000 ppm, ANIMAL NO. 0329-1345 (H&E)
- PHOTOGRAPH 3 LIVER: HEPATOCELLULAR CARCINOMA,
MOUSE, MALE, 2000 ppm, ANIMAL NO. 0329-1325 (H&E)
- PHOTOGRAPH 4 LIVER: HEPATOBLASTOMA,
MOUSE, MALE, 800 ppm, ANIMAL NO. 0329-1215 (H&E)
- PHOTOGRAPH 5 LIVER: HEPATOCELLULAR ADENOMA,
MOUSE, FEMALE, 2000 ppm, ANIMAL NO. 0329-2339 (H&E)
- PHOTOGRAPH 6 LIVER: HEPATOCELLULAR CARCINOMA,
MOUSE, FEMALE, 2000 ppm, ANIMAL NO. 0329-2330 (H&E)
- PHOTOGRAPH 7 LIVER: ACIDOPHILIC CELL FOCUS,
MOUSE, MALE, 800 ppm, ANIMAL NO. 0329-1225 (H&E)
- PHOTOGRAPH 8 KIDNEY: DEPOSIT OF HEMOSIDERIN,
MOUSE, MALE, 2000 ppm, ANIMAL NO. 0329-1304 (H&E)
- PHOTOGRAPH 9 NASAL CAVITY (RESPIRATORY EPITHELIUM): NORMAL,
MOUSE, FEMALE, CONTROL, ANIMAL NO. 0329-2012 (H&E)
- PHOTOGRAPH 10 NASAL CAVITY: EOSINOPHILIC CHANGE OF THE RESPIRATORY
EPITHELIUM,
MOUSE, FEMALE, 2000 ppm, ANIMAL NO. 0329-2329 (H&E)
- PHOTOGRAPH 11 NASAL CAVITY (OLFACTORY EPITHELIUM): NORMAL,
MOUSE, FEMALE, CONTROL, ANIMAL NO. 0329-2005 (H&E)
- PHOTOGRAPH 12 NASAL CAVITY: RESPIRATORY METAPLASIA OF THE GLAND (A)
AND OLFACTORY EPITHELIUM (B)
MOUSE, FEMALE, 2000 ppm, ANIMAL NO. 0329-2316 (H&E)



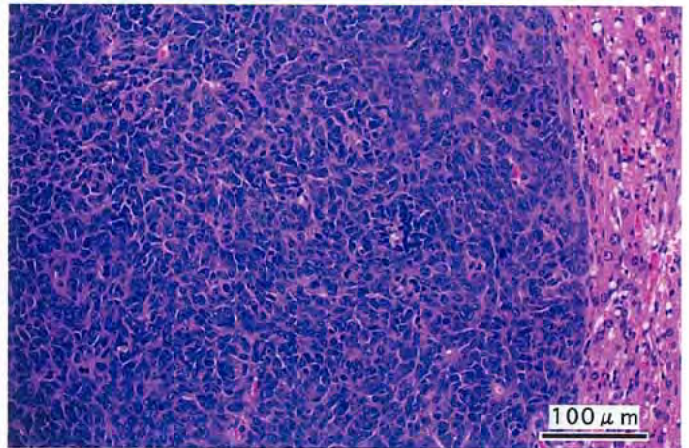
PHOTOGRAPH. 1



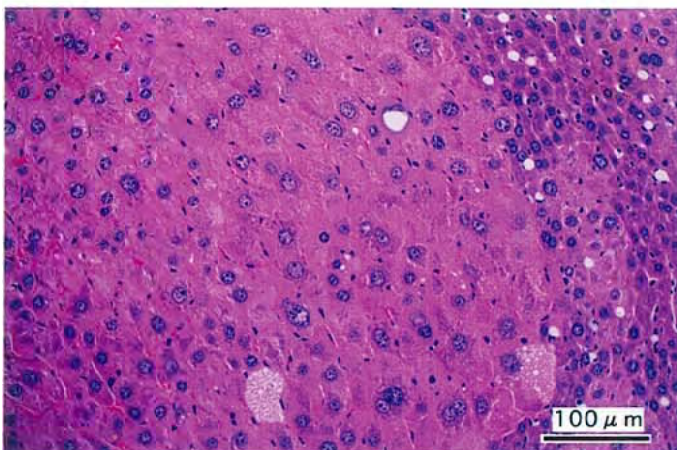
PHOTOGRAPH. 2



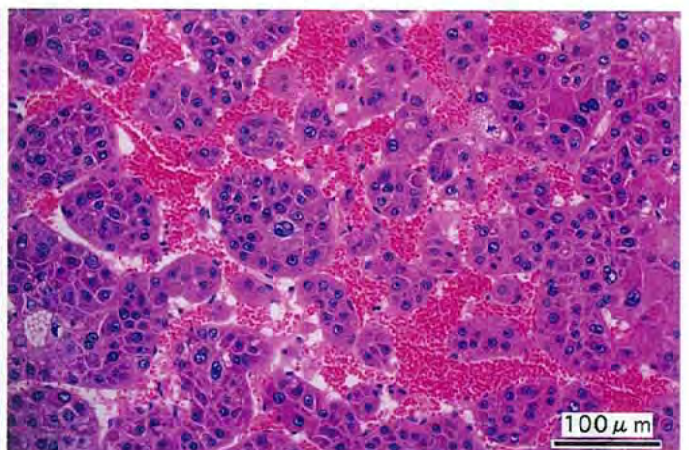
PHOTOGRAPH. 3



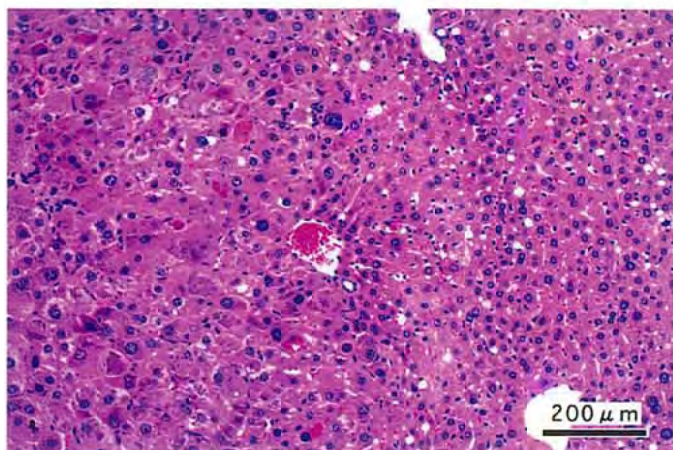
PHOTOGRAPH. 4



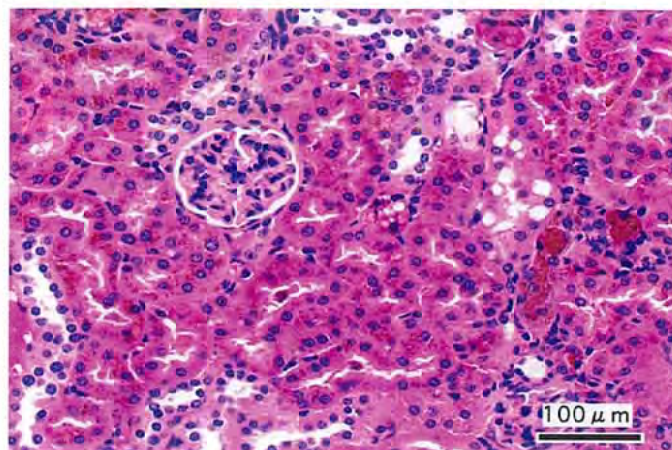
PHOTOGRAPH. 5



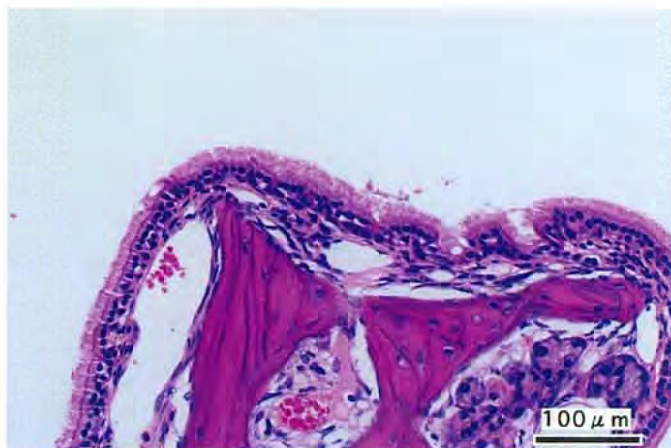
PHOTOGRAPH. 6



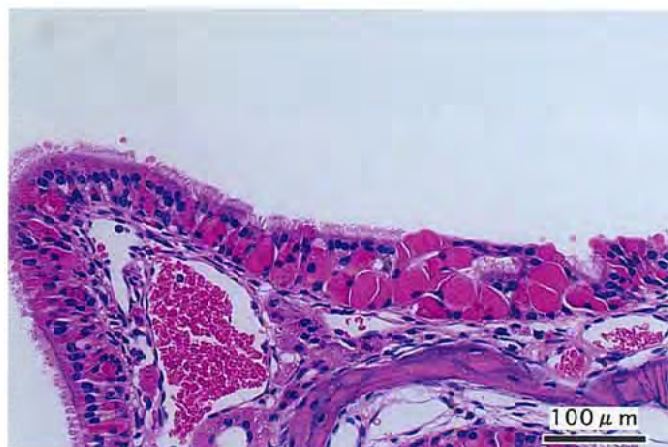
PHOTOGRAPH. 7



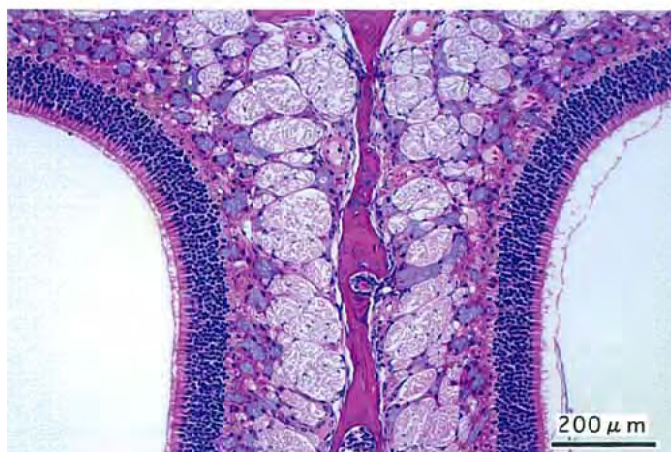PHOTOGRAPH. 8



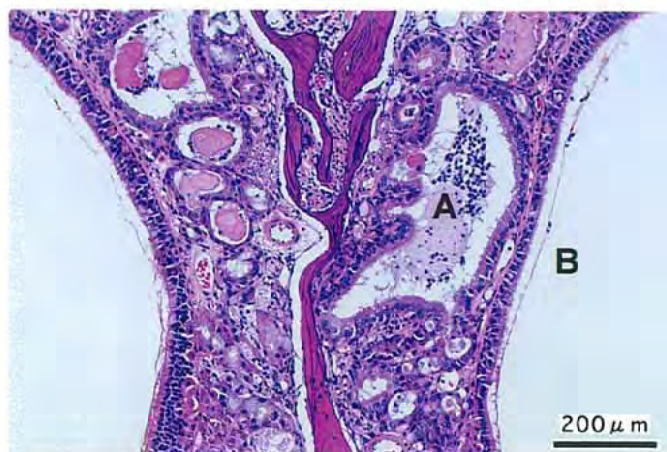
PHOTOGRAPH. 9



PHOTOGRAPH. 10



PHOTOGRAPH. 11



PHOTOGRAPH. 12