

キノリンのマウスを用いた経口投与による
がん原性試験(混水試験)報告書

試験番号：0304

PHOTOGRAPHS

PHOTOGRAPHS

- PHOTOGRAPH 1 RETROPERITONEUM: RED MASS (ARROW) (HEMANGIOSARCOMA)
MOUSE, MALE, 150ppm, ANIMAL NO. 0304-1104
- PHOTOGRAPH 2 MESENTERIUM: RED MASS (ARROW) (HEMANGIOSARCOMA)
MOUSE, MALE, 600ppm, ANIMAL NO. 0304-1328
- PHOTOGRAPH 3 SUBCUTIS: RED MASS (ARROW) (HEMANGIOSARCOMA)
MOUSE, FEMALE, 600ppm, ANIMAL NO. 0304-2344
- PHOTOGRAPH 4 RETROPERITONEUM: HEMANGIOMA
MOUSE, FEMALE, 150ppm, ANIMAL NO. 0304-2129 (H&E)
- PHOTOGRAPH 5 RETROPERITONEUM: HEMANGIOSARCOMA (ARROW)
MOUSE, MALE, 300ppm, ANIMAL NO. 0304-1218 (H&E)
- PHOTOGRAPH 6 RETROPERITONEUM: HEMANGIOSARCOMA
HIGHER MAGNIFICATION OF PHOTOGRAPH 5
MOUSE, MALE, 300ppm, ANIMAL NO. 0304-1218 (H&E)
- PHOTOGRAPH 7 MESENTERIUM: HEMANGIOMA (ARROW)
MOUSE, FEMALE, 150ppm, ANIMAL NO. 0304-2117 (H&E)
- PHOTOGRAPH 8 MESENTERIUM: HEMANGIOMA
HIGHER MAGNIFICATION OF PHOTOGRAPH 7
MOUSE, FEMALE, 150ppm, ANIMAL NO. 0304-2117 (H&E)
- PHOTOGRAPH 9 MESENTERIUM: HEMANGIOSARCOMA (ARROW)
MOUSE, FEMALE, 300ppm, ANIMAL NO. 0304-2225 (H&E)
- PHOTOGRAPH 10 MESENTERIUM: HEMANGIOSARCOMA
HIGHER MAGNIFICATION OF PHOTOGRAPH 9
MOUSE, FEMALE, 300ppm, ANIMAL NO. 0304-2225 (H&E)
- PHOTOGRAPH 11 SUBCUTIS: HEMANGIOSARCOMA (ARROW)
MOUSE, FEMALE, 600ppm, ANIMAL NO. 0304-2303 (H&E)

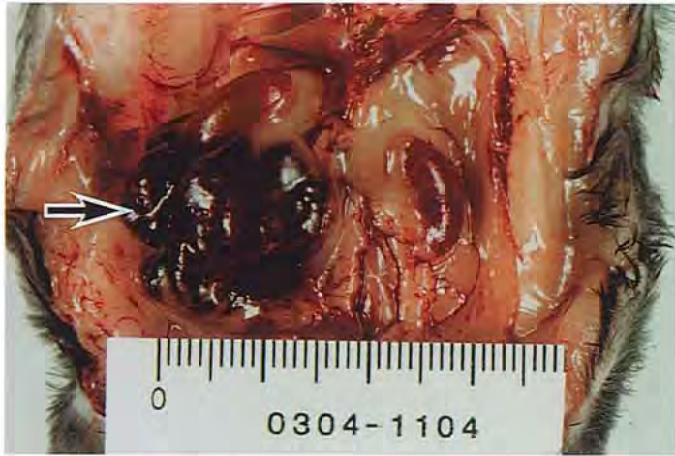PHOTOGRAPHS(CONTINUED)

- PHOTOGRAPH 12 SUBCUTIS: HEMANGIOSARCOMA (ARROW)
HIGHER MAGNIFICATION OF PHOTOGRAPH 11
MOUSE, FEMALE, 600ppm, ANIMAL NO. 0304-2303 (H&E)
- PHOTOGRAPH 13 LIVER: HEMANGIOMA (ARROW)
MOUSE, FEMALE, 600ppm, ANIMAL NO. 0304-2319 (H&E)
- PHOTOGRAPH 14 LIVER: HEMANGIOSARCOMA (ARROW)
MOUSE, MALE, 600ppm, ANIMAL NO. 0304-1307 (H&E)
- PHOTOGRAPH 15 PERITONEUM (PLICA LATA UTERI): HEMANGIOMA (ARROW)
MOUSE, FEMALE, 300ppm, ANIMAL NO. 0304-2236 (H&E)
- PHOTOGRAPH 16 PERITONEUM (PLICA LATA UTERI): HEMANGIOSARCOMA
(ARROW)
MOUSE, FEMALE, 600ppm, ANIMAL NO. 0304-2332 (H&E)
- PHOTOGRAPH 17 MEDIASTINUM: HEMANGIOSARCOMA (ARROW)
MOUSE, FEMALE, 150ppm, ANIMAL NO. 0304-2104 (H&E)
- PHOTOGRAPH 18 OVARY: HEMANGIOSARCOMA (ARROW)
MOUSE, FEMALE, 300ppm, ANIMAL NO. 0304-2232 (H&E)
- PHOTOGRAPH 19 LUNG: METASTASIS OF HEMANGIOSARCOMA FROM THE
RETROPERITONEUM (ARROW)
MOUSE, FEMALE, 150ppm, ANIMAL NO. 0304-2138 (H&E)
- PHOTOGRAPH 20 LUNG: METASTASIS OF HEMANGIOSARCOMA FROM THE
MESENTERIUM (ARROW)
MOUSE, MALE, 300ppm, ANIMAL NO. 0304-1212 (H&E)
- PHOTOGRAPH 21 LYMPH NODE: METASTASIS OF HEMANGIOSARCOMA
FROM THE SUBCUTIS (ARROW)
MOUSE, FEMALE, 300ppm, ANIMAL NO. 0304-2204 (H&E)
- PHOTOGRAPH 22 LIVER: HISTIOCYTIC SARCOMA (ARROW)
MOUSE, FEMALE, 600ppm, ANIMAL NO. 0304-2336 (H&E)

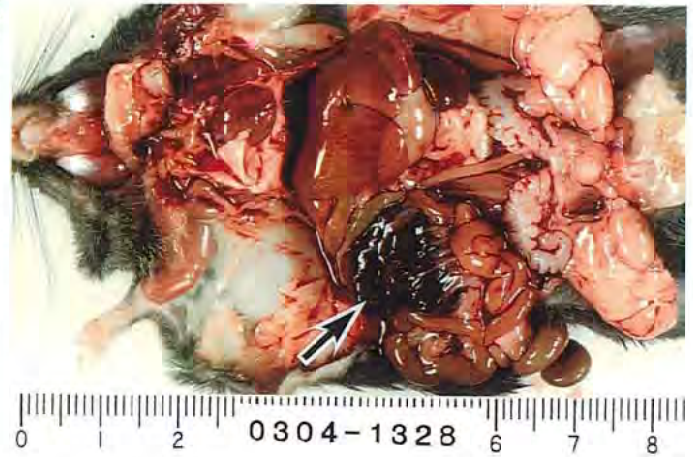PHOTOGRAPHS(CONTINUED)

PHOTOGRAPH 23 LIVER: HEPATOCELLULAR CARCINOMA (ARROW)
MOUSE, MALE, 150ppm, ANIMAL NO. 0304-1143 (H&E)

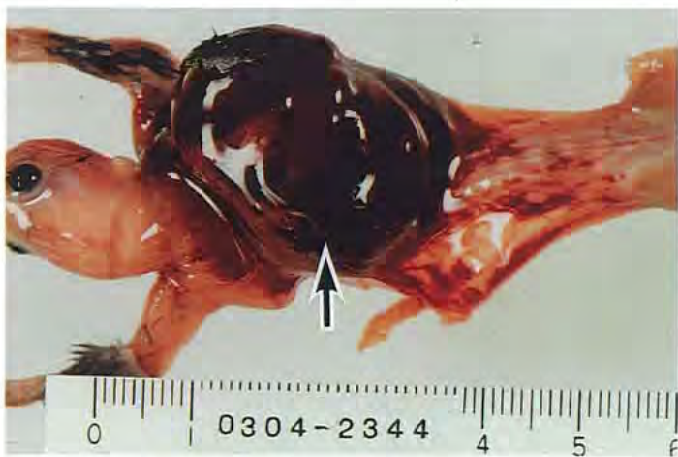PHOTOGRAPH 24 KIDNEY: RENAL CELL CARCINOMA (ARROW)
MOUSE, MALE, 600ppm, ANIMAL NO. 0304-1302 (H&E)



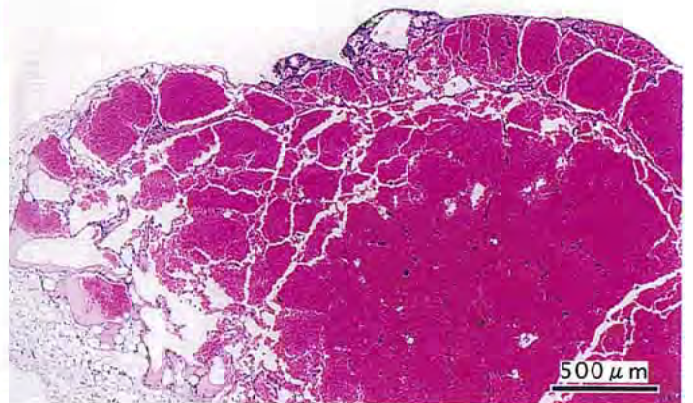
PHOTOGRAPH 1



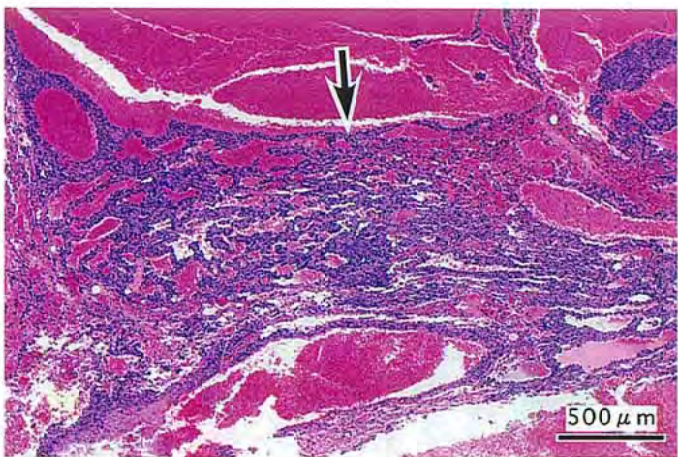
PHOTOGRAPH 2



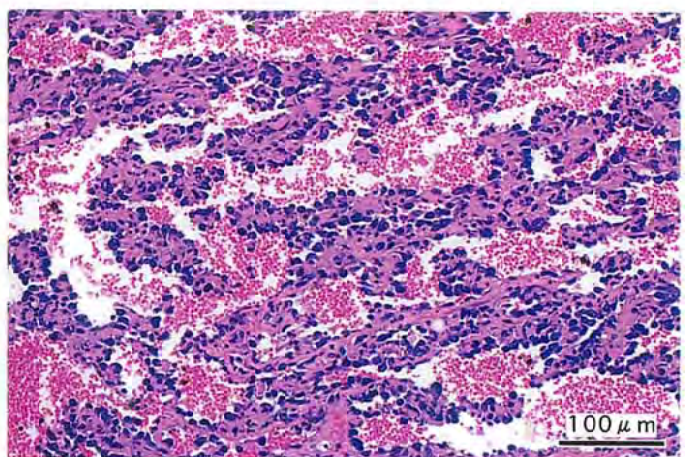
PHOTOGRAPH 3



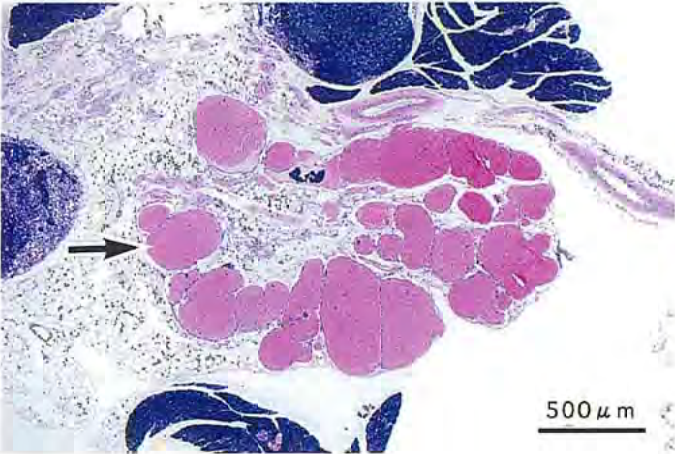
PHOTOGRAPH 4



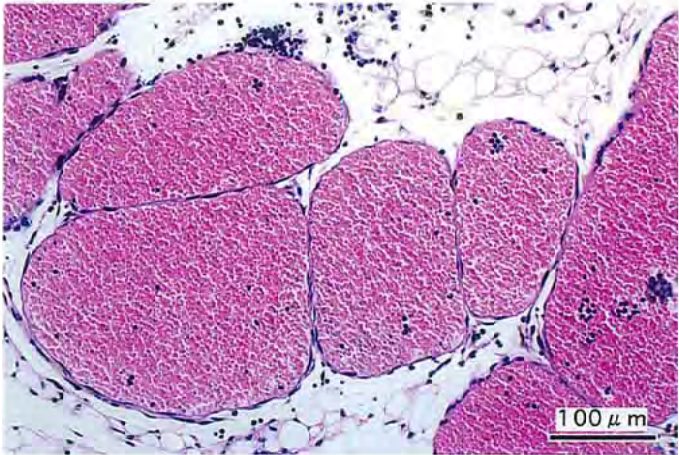PHOTOGRAPH 5



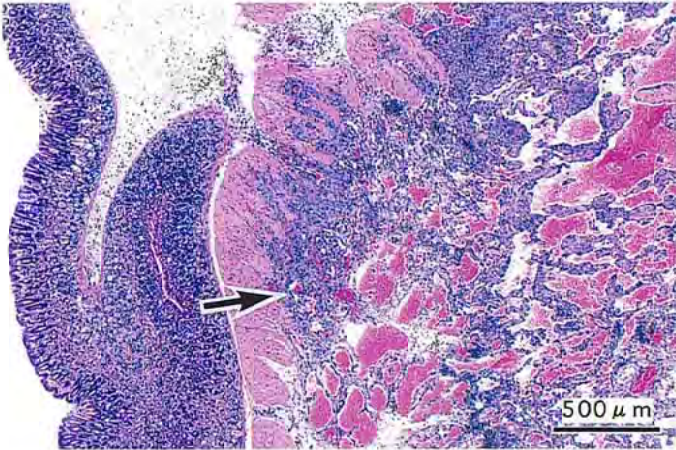
PHOTOGRAPH 6



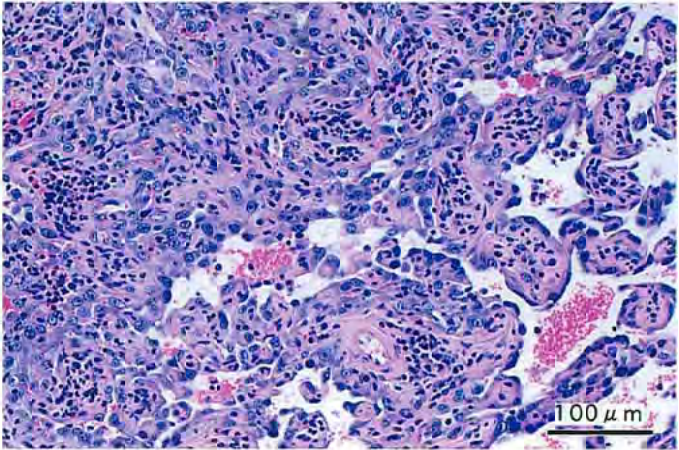
PHOTOGRAPH 7



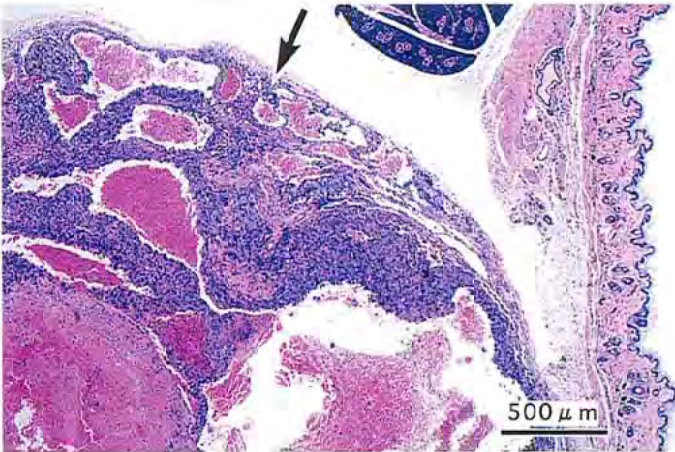
PHOTOGRAPH 8



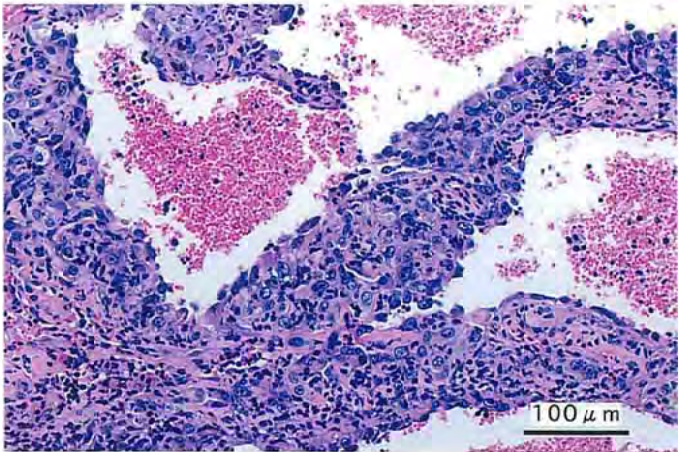
PHOTOGRAPH 9



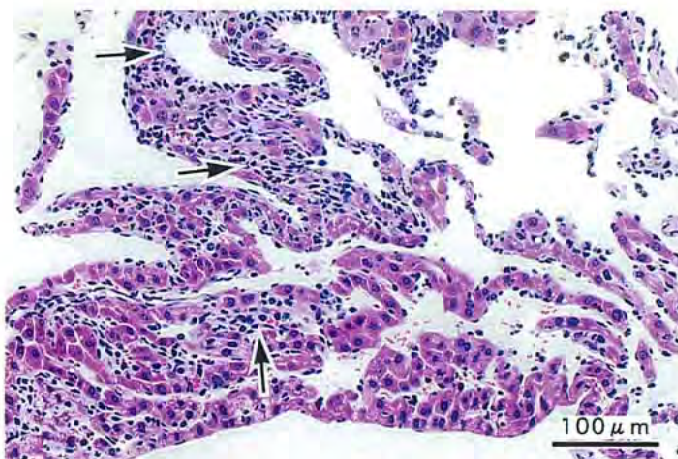
PHOTOGRAPH 10



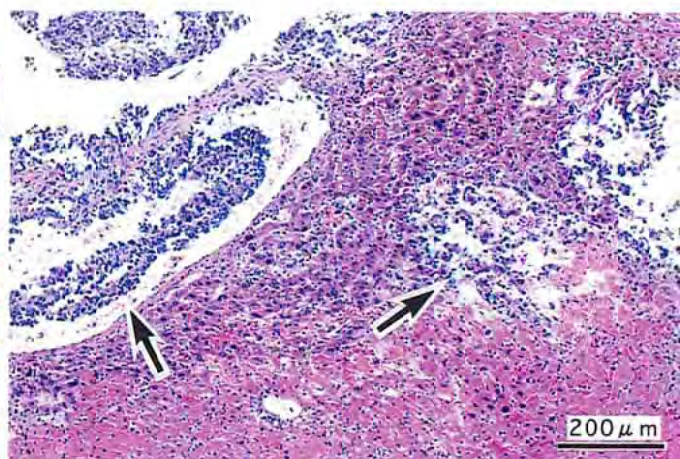
PHOTOGRAPH 11



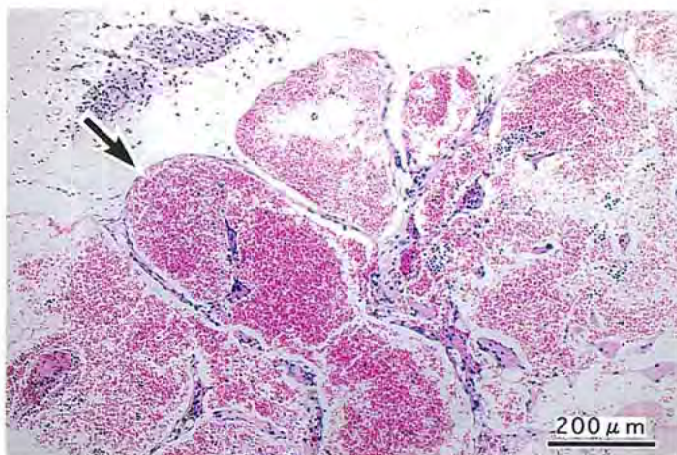
PHOTOGRAPH 12



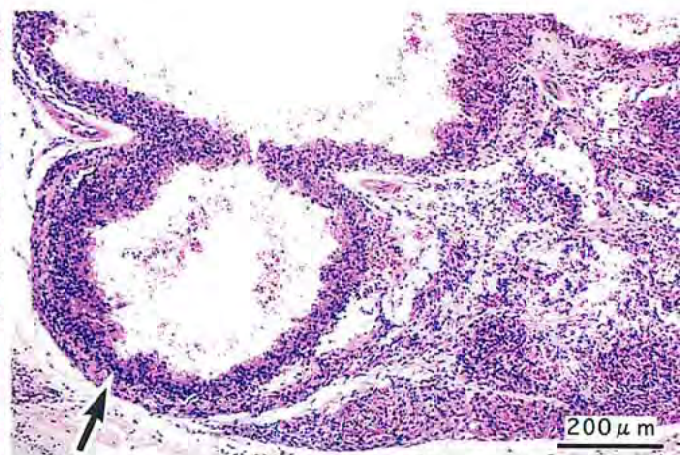
PHOTOGRAPH 13



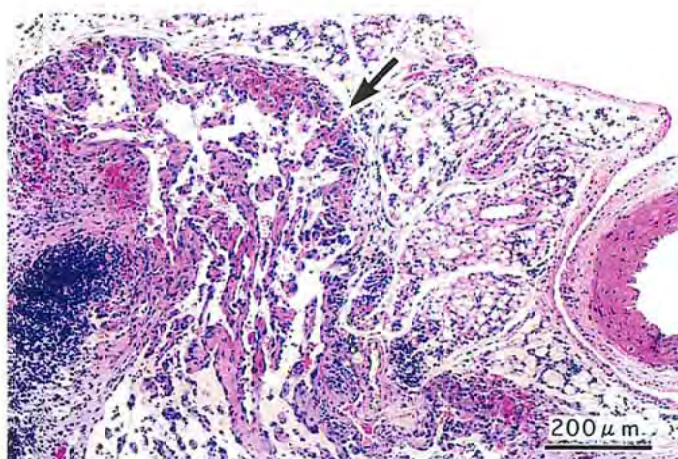
PHOTOGRAPH 14



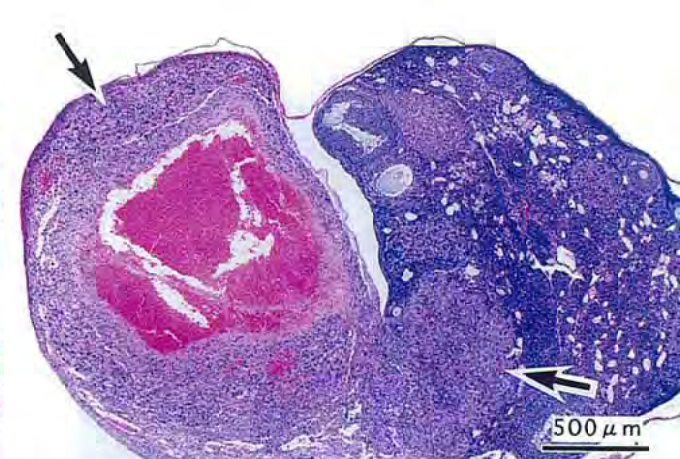
PHOTOGRAPH 15



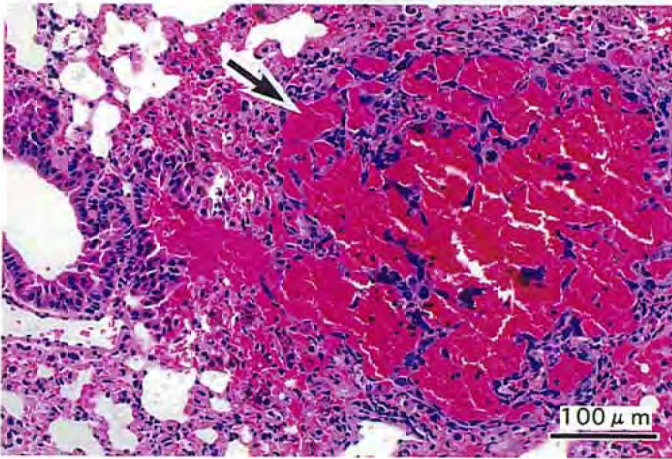
PHOTOGRAPH 16



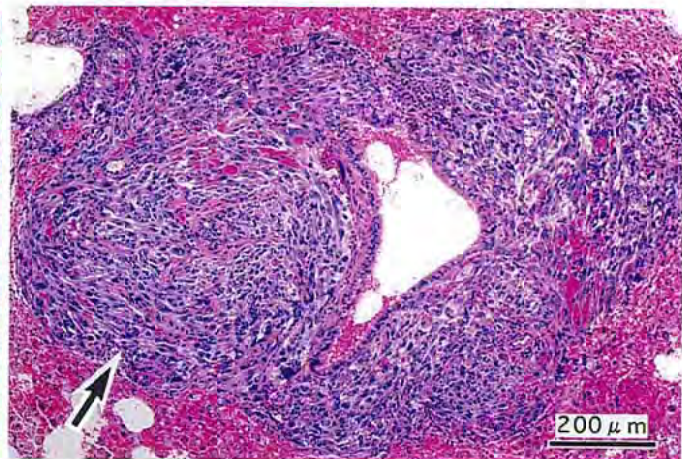
PHOTOGRAPH 17



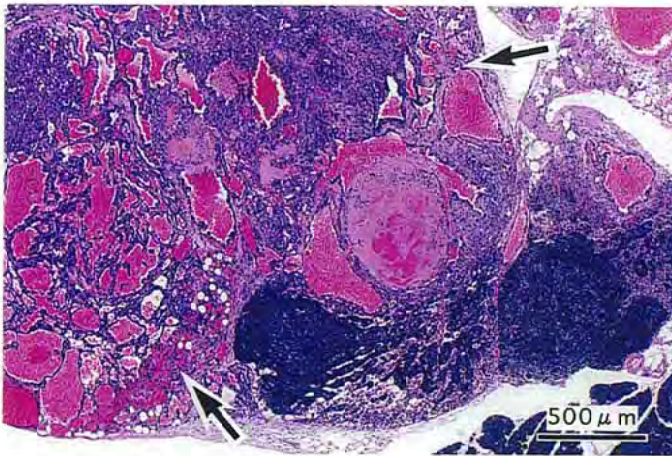
PHOTOGRAPH 18



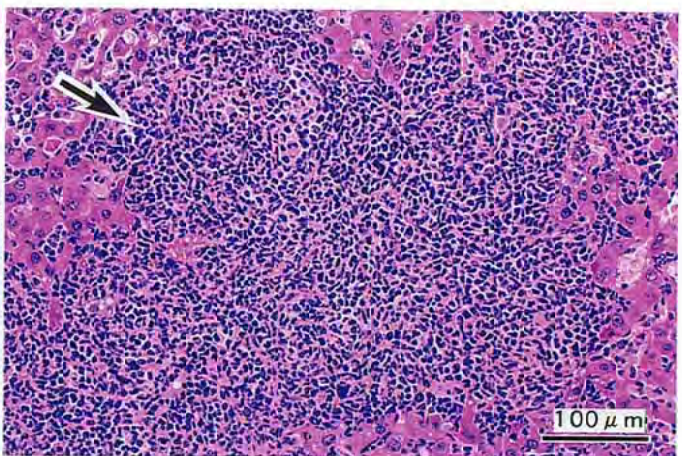
PHOTOGRAPH 19



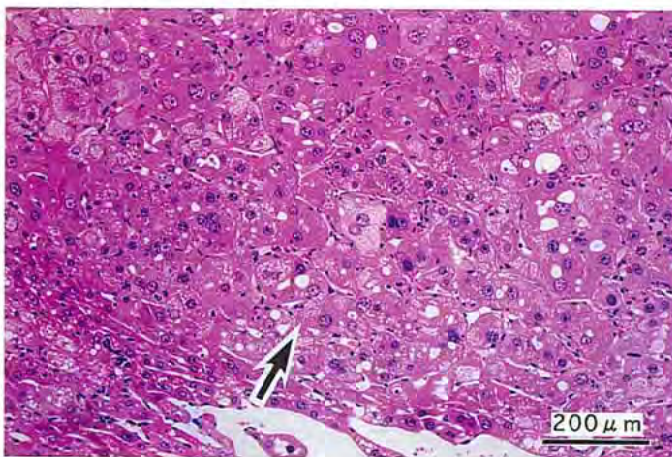
PHOTOGRAPH 20



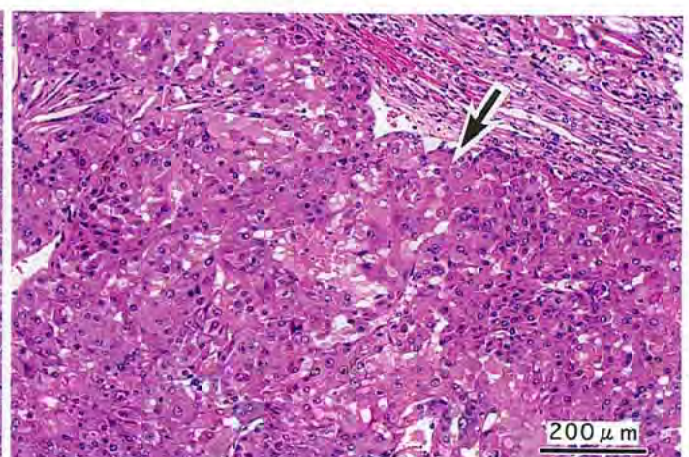
PHOTOGRAPH 21



PHOTOGRAPH 22



PHOTOGRAPH 23



PHOTOGRAPH 24