

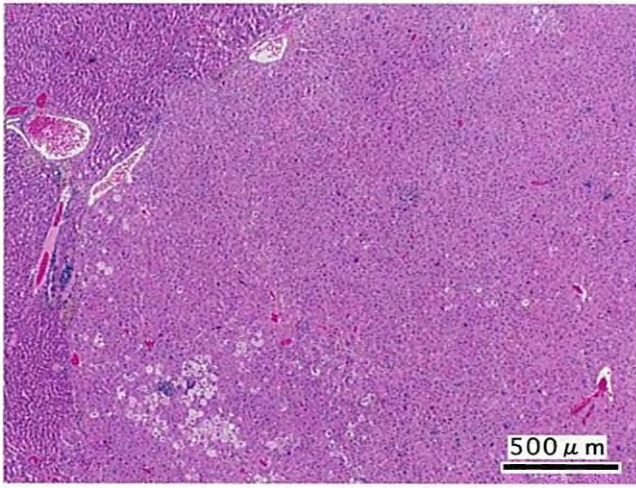
N,N-ジメチルホルムアミドのマウスを用いた
吸入によるがん原性試験報告書

試験番号 : 0297

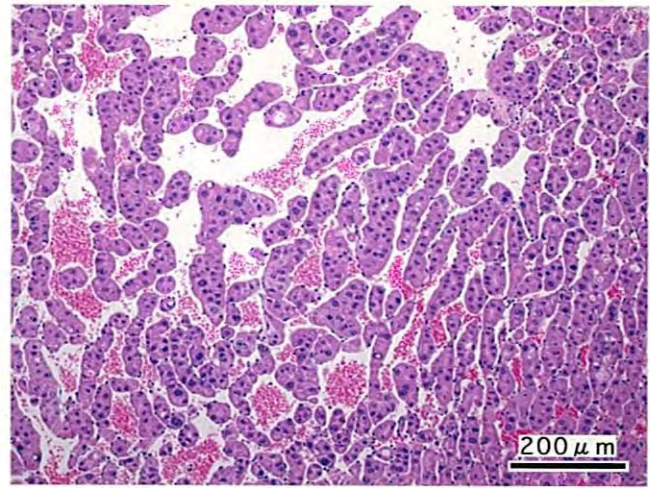
PHOTOGRAPHS

PHOTOGRAPHS

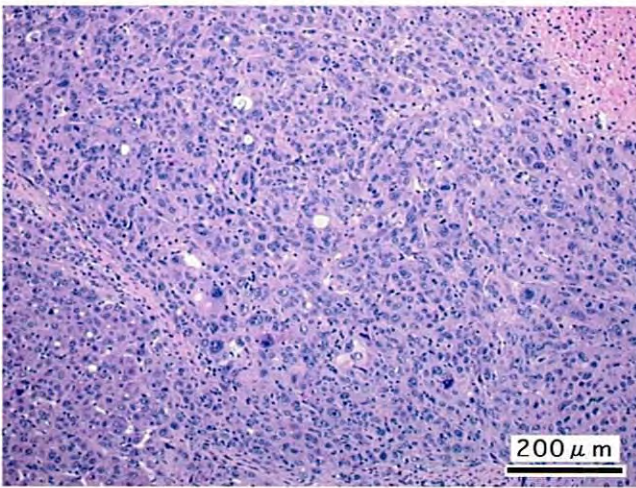
- PHOTOGRAPH 1 LIVER : HEPATOCELLULAR ADENOMA
MALE, 200ppm, ANIMAL No. 0297-1131 (H&E)
- PHOTOGRAPH 2 LIVER : HEPATOCELLULAR ADENOMA
HIGHER MAGNIFICATION OF PHOTOGRAPH 1
- PHOTOGRAPH 3 LIVER : HEPATOCELLULAR CARCINOMA
MALE, 400ppm, ANIMAL No. 0297-1218 (H&E)
- PHOTOGRAPH 4 LIVER : HEPATOCELLULAR CARCINOMA
HIGHER MAGNIFICATION OF PHOTOGRAPH 3
- PHOTOGRAPH 5 LIVER : HEPATOBLASTOMA
MALE, 800ppm, ANIMAL No. 0297-1308 (H&E)
- PHOTOGRAPH 6 LIVER : HEPATOBLASTOMA
HIGHER MAGNIFICATION OF PHOTOGRAPH 5
- PHOTOGRAPH 7 LIVER : CLEAR CELL FOCUS
MALE, 200ppm, ANIMAL No. 0297-1107 (H&E)
- PHOTOGRAPH 8 LIVER : ACIDPHYLIC CELL FOCUS
MALE, 200ppm, ANIMAL No. 0297-1131 (H&E)
- PHOTOGRAPH 9 LIVER : SWELLING:CENTRAL
MALE, 800ppm, ANIMAL No. 0297-1315 (H&E)
- PHOTOGRAPH 10 LIVER : SINGLE CELL NECROSIS (A)
INFLAMMATORY CELL INFILTRATION (B)
NUCLEAR ENLARGEMENT (C)
MALE, 800ppm, ANIMAL No. 0297-1301 (H&E)



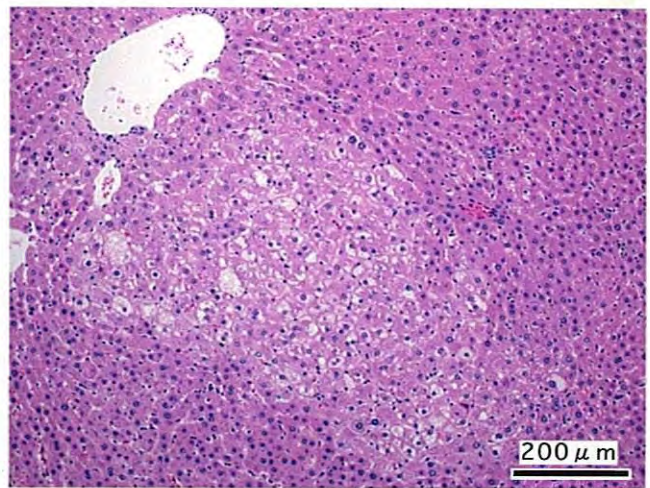
PHOTOGRAPH. 1



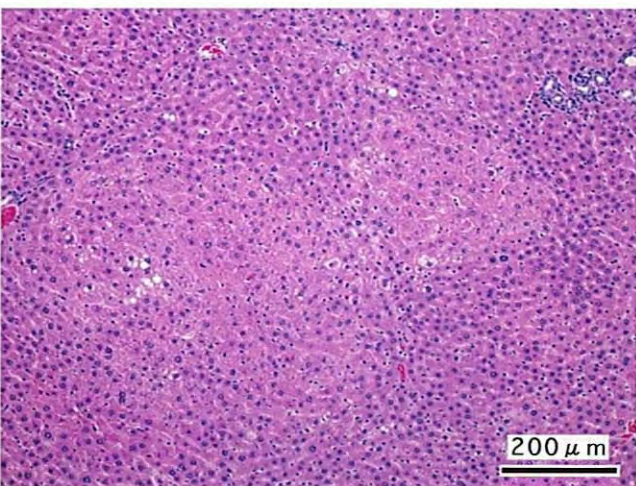
PHOTOGRAPH. 2



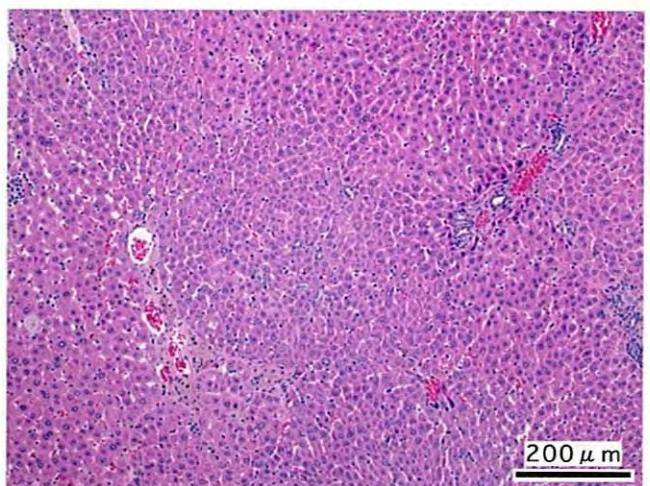
PHOTOGRAPH. 3



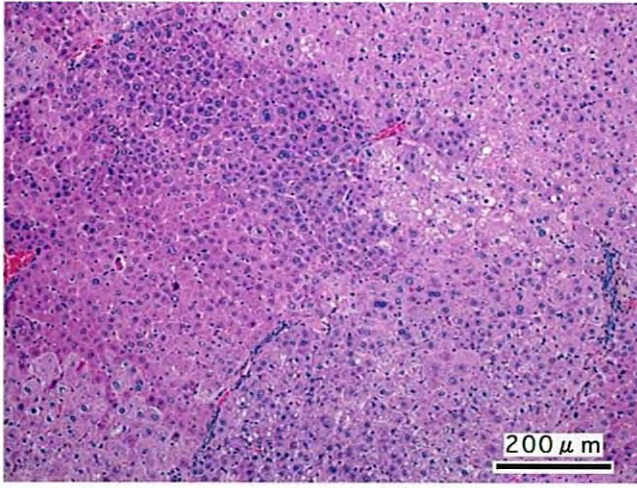
PHOTOGRAPH. 4



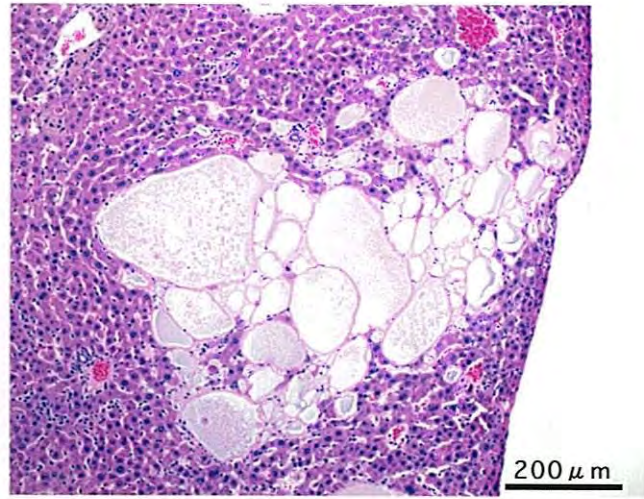
PHOTOGRAPH. 5



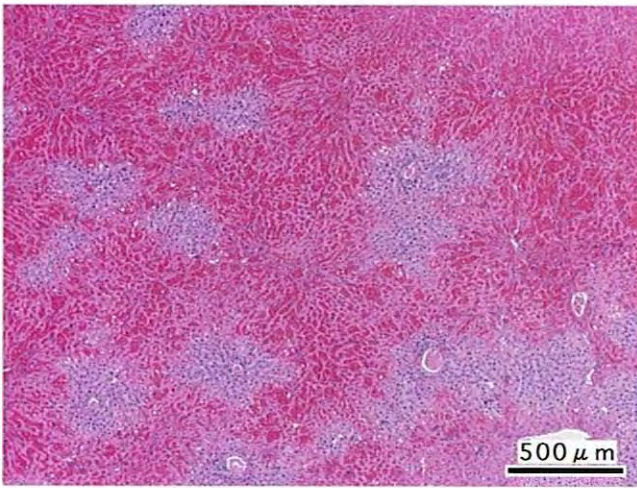
PHOTOGRAPH. 6



PHOTOGRAPH. 7



PHOTOGRAPH. 8



PHOTOGRAPH. 9