

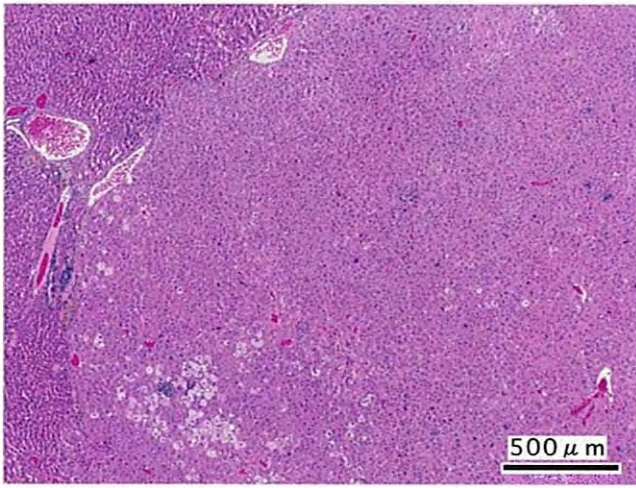
*N,N*-ジメチルホルムアミドのラットを用いた  
吸入によるがん原性試験報告書

試験番号 : 0296

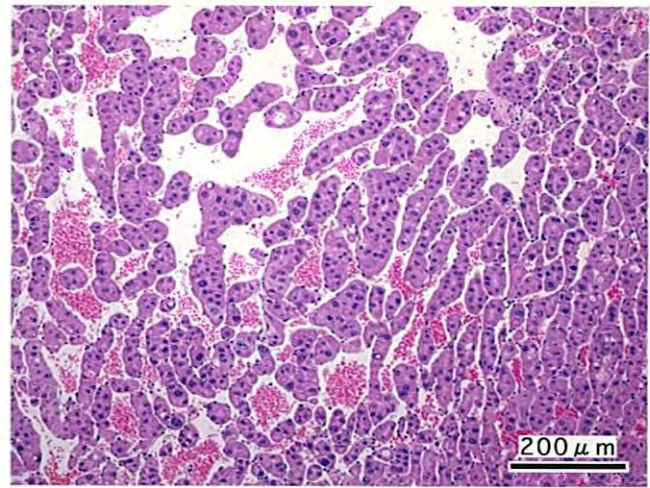
# PHOTOGRAPHS

## PHOTOGRAPHS

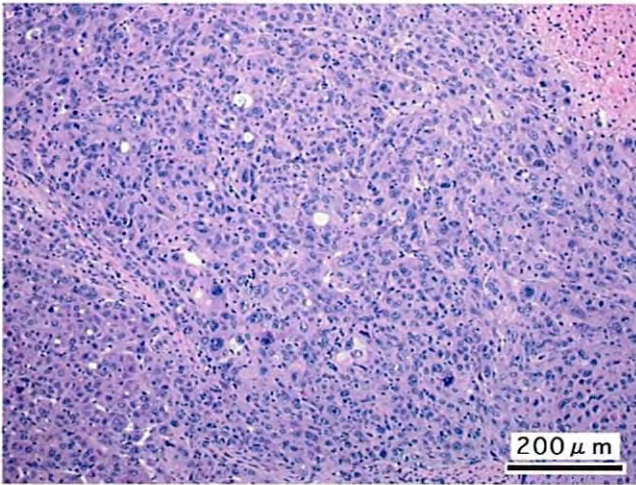
- PHOTOGRAPH 1 LIVER : HEPATOCELLULAR ADENOMA  
FEMALE, 800ppm, ANIMAL No. 0296-2302 ( H&E )
- PHOTOGRAPH 2 LIVER : HEPATOCELLULAR CARCINOMA  
FEMALE, 800ppm, ANIMAL No. 0296-2336 ( H&E )
- PHOTOGRAPH 3 LIVER : HEPATOCELLULAR CARCINOMA  
MALE, 800ppm, ANIMAL No. 0296-1316 ( H&E )
- PHOTOGRAPH 4 LIVER : CLEAR CELL FOCUS  
MALE, 800ppm, ANIMAL No. 0296-1302 ( H&E )
- PHOTOGRAPH 5 LIVER : ACIDPHYLIC CELL FOCUS  
MALE, 400ppm, ANIMAL No. 0296-1232 ( H&E )
- PHOTOGRAPH 6 LIVER : BASOPHYLIC CELL FOCUS  
FEMALE, 800ppm, ANIMAL No. 0296-2328 ( H&E )
- PHOTOGRAPH 7 LIVER : MIXED CELL FOCUS  
MALE, 800ppm, ANIMAL No. 0296-1318 ( H&E )
- PHOTOGRAPH 8 LIVER : SPONGIOSIS HEPATIS  
MALE, 800ppm, ANIMAL No. 0296-1303 ( H&E )
- PHOTOGRAPH 9 LIVER : NECROSIS:CENTRAL (DEAD: 7DAYS)  
MALE, 800ppm, ANIMAL No. 0296-1312 ( H&E )



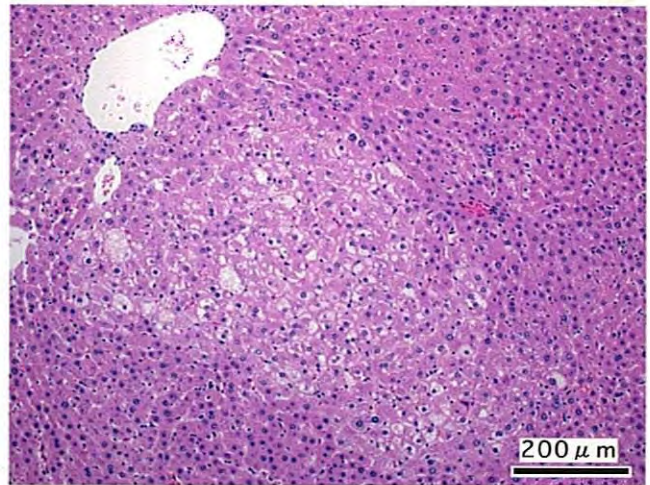
PHOTOGRAPH. 1



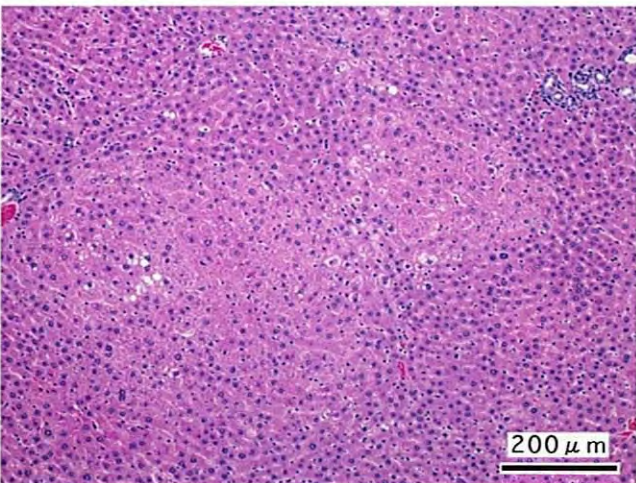
PHOTOGRAPH. 2



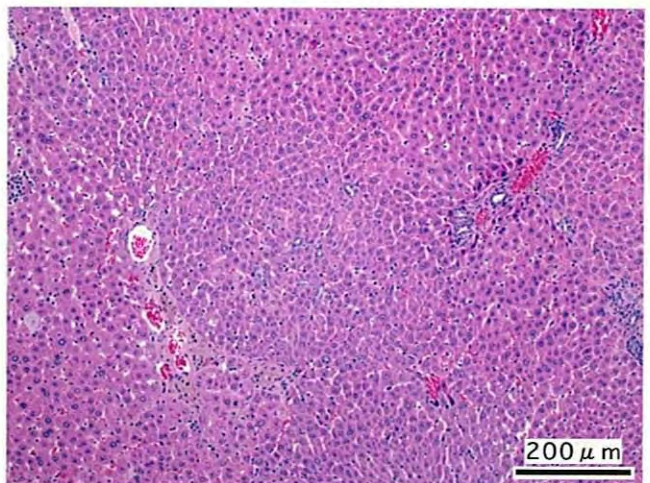
PHOTOGRAPH. 3



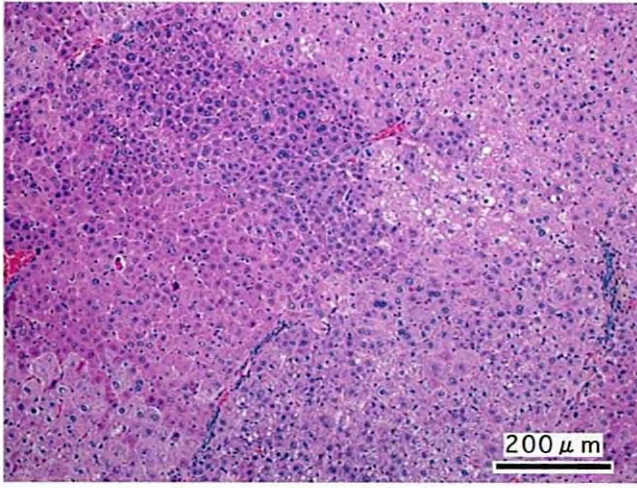
PHOTOGRAPH. 4



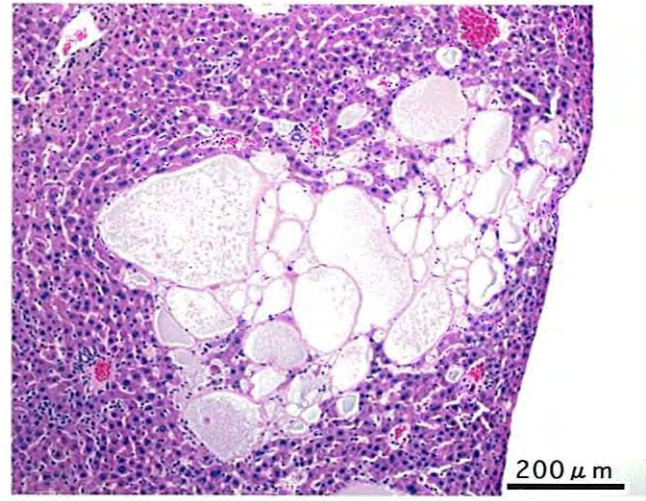
PHOTOGRAPH. 5



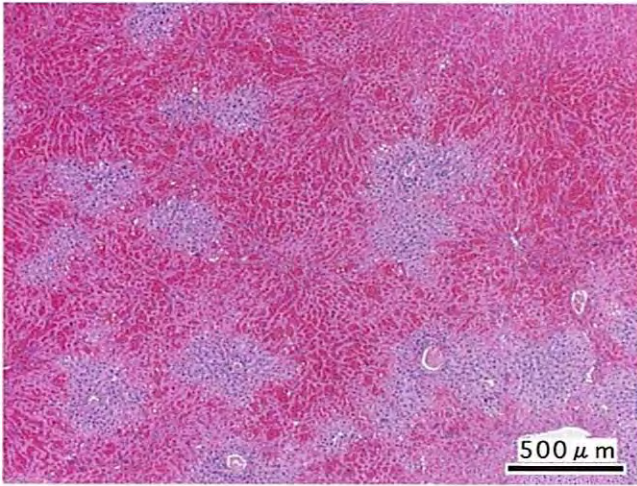
PHOTOGRAPH. 6



PHOTOGRAPH. 7



PHOTOGRAPH. 8



PHOTOGRAPH. 9