

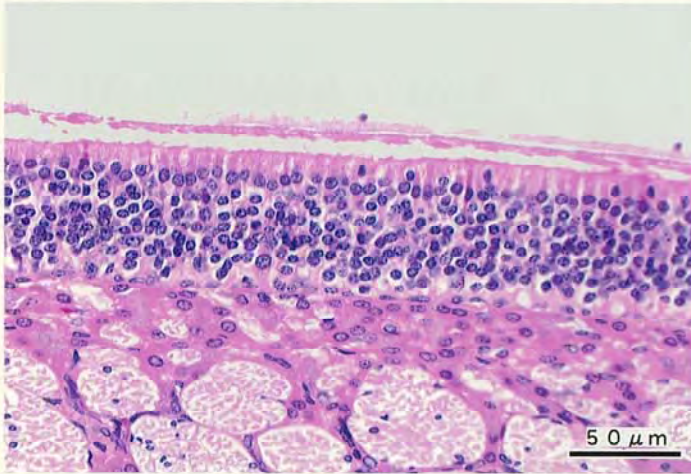
キノリンのラットを用いた経口投与による  
13 週間毒性試験(混水試験)報告書

試験番号：0289

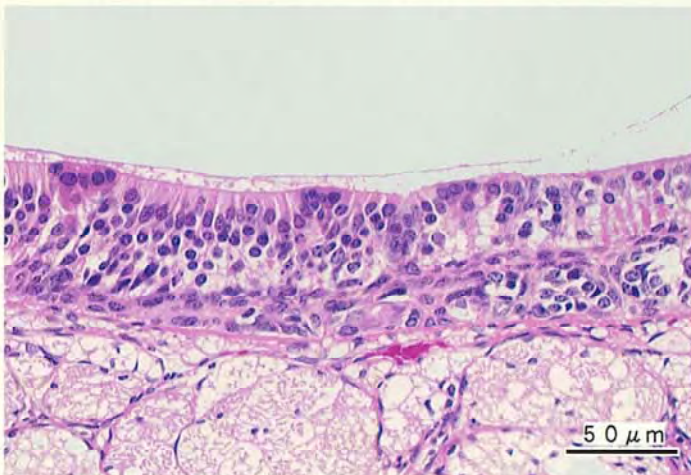
**PHOTOGRAPHS**

## PHOTOGRAPHS

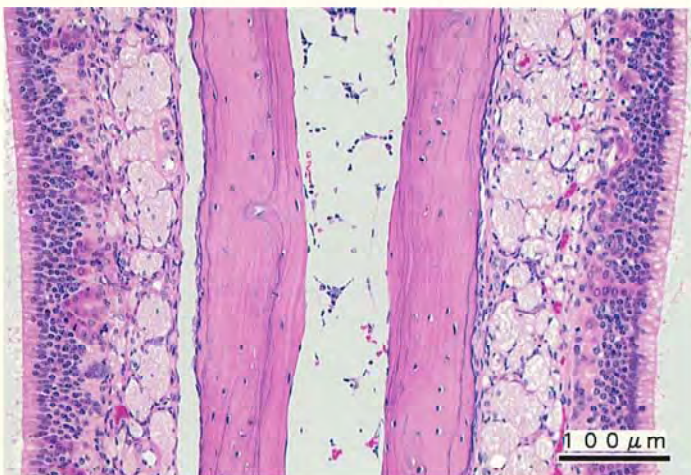
- PHOTOGRAPH 1      NASAL CAVITY: NORMAL: OLFACTORY EPITHELIUM  
RAT, MALE, CONTROL, ANIMAL NO. 0289-1005 (H&E)
- PHOTOGRAPH 2      NASAL CAVITY: MULTINUCLEAR LIKE CHANGE OF SUPPORTING CELL  
RAT, MALE, 800ppm, ANIMAL No. 0289-1501 (H&E)
- PHOTOGRAPH 3      NASAL CAVITY: MANIFESTATION OF DUCT OF OLFACTORY GLAND:  
OLFACTORY EPITHELIUM  
RAT, MALE, 800ppm, ANIMAL No. 0289-1509 (H&E)
- PHOTOGRAPH 4      LIVER: VACUOLIC CHANGE: SINGLE CELL  
RAT, MALE, 800ppm, ANIMAL No. 0289-1509 (H&E)



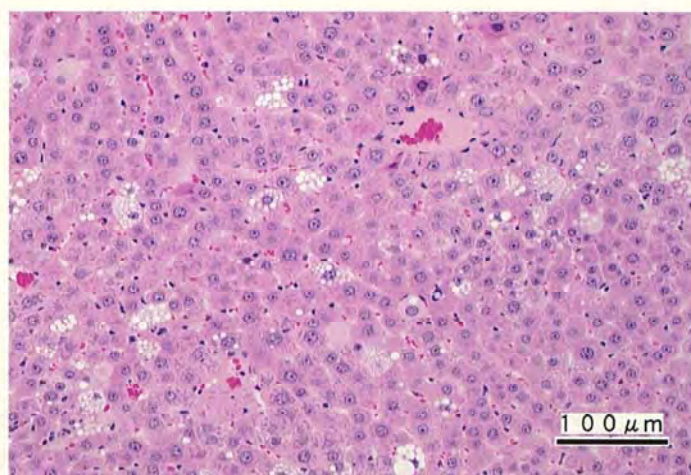
PHOTOGRAPH 1



PHOTOGRAPH 2



PHOTOGRAPH 3



PHOTOGRAPH 4