

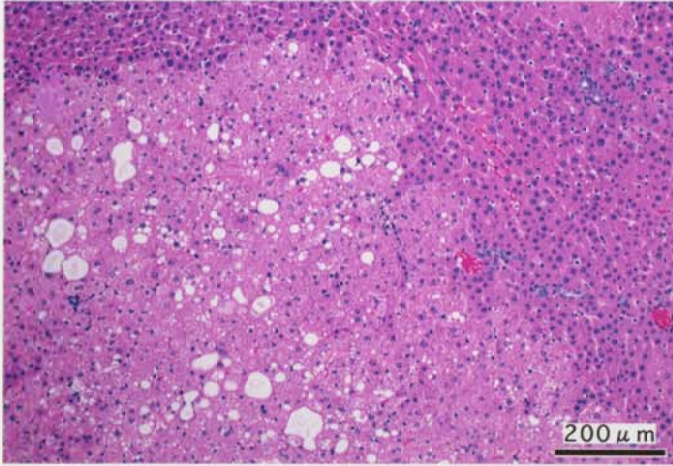
ヒドラジナー水加物のラットを用いた
経口投与によるがん原性試験(混水試験)報告書

試験番号 : 0284

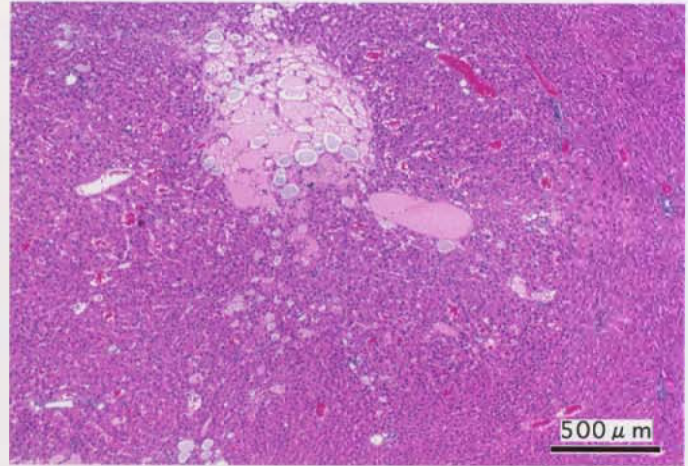
PHOTOGRAPHS

PHOTOGRAPHS

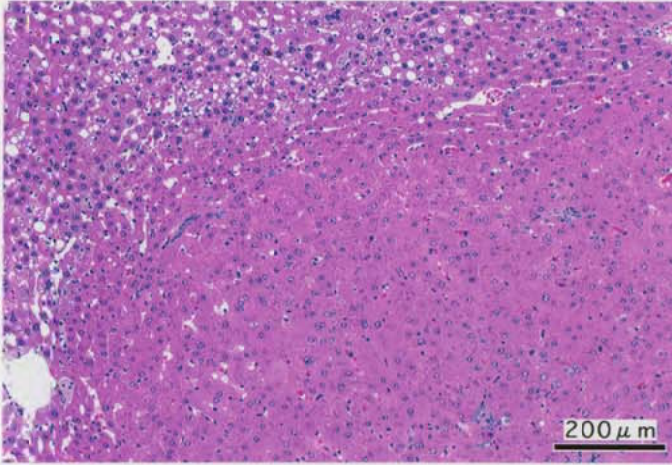
- PHOTOGRAPH 1 LIVER: ACIDOPHILIC CELL FOCUS,
RAT, MALE, 80ppm, ANIMAL NO. 0284-1315 (H&E)
- PHOTOGRAPH 2 LIVER: BASOPHILIC CELL FOCUS,
RAT, MALE, 80ppm, ANIMAL NO. 0284-1319 (H&E)
- PHOTOGRAPH 3 LIVER: HEPATOCELLULAR ADENOMA,
RAT, FEMALE, 80ppm, ANIMAL NO. 0284-2306 (H&E)
- PHOTOGRAPH 4 KIDNEY: HEPATOCELLULAR CARCINOMA,
RAT, FEMALE, 80ppm, ANIMAL NO. 0284-2334 (H&E)
- PHOTOGRAPH 5 KIDNEY: INFRACT,
RAT, FEMALE, 80ppm, ANIMAL NO. 0284-2343 (H&E)
- PHOTOGRAPH 6 KIDNEY:(A) PAPILLARY NECROSIS
(B) MINERALIZATION PAPILLA
(C) UROTHELIAL HYPERPLASIA: PELVIS
RAT, FEMALE, 80ppm, ANIMAL NO. 0284-2343(H&E)



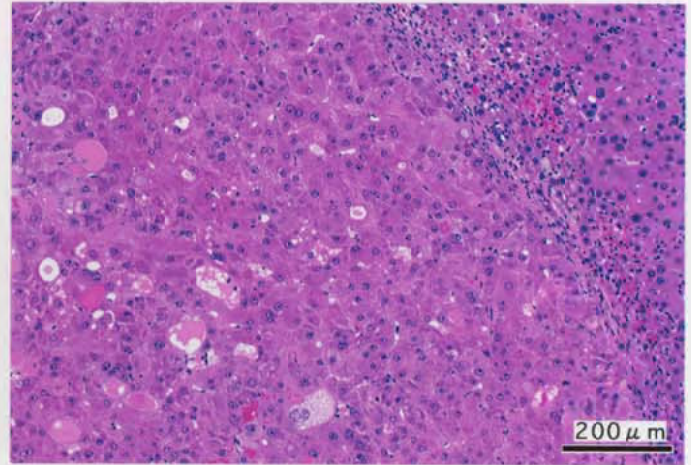
PHOTOGRAPH. 1



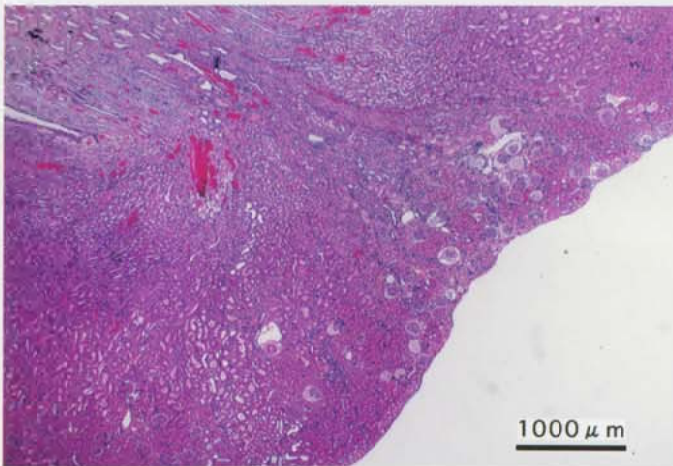
PHOTOGRAPH. 2



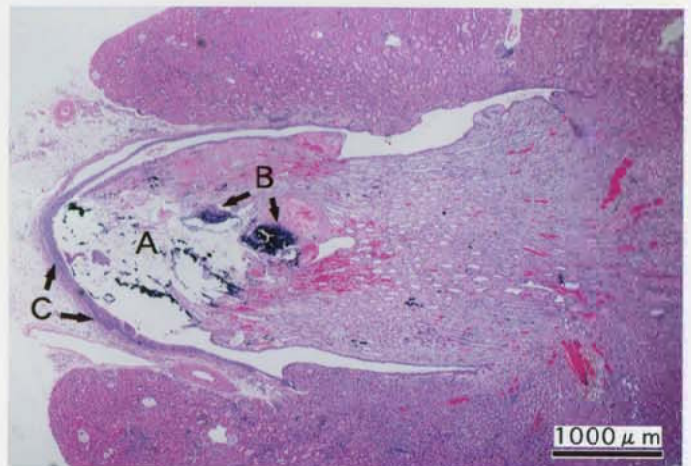
PHOTOGRAPH. 3



PHOTOGRAPH. 4



PHOTOGRAPH. 5



PHOTOGRAPH. 6