

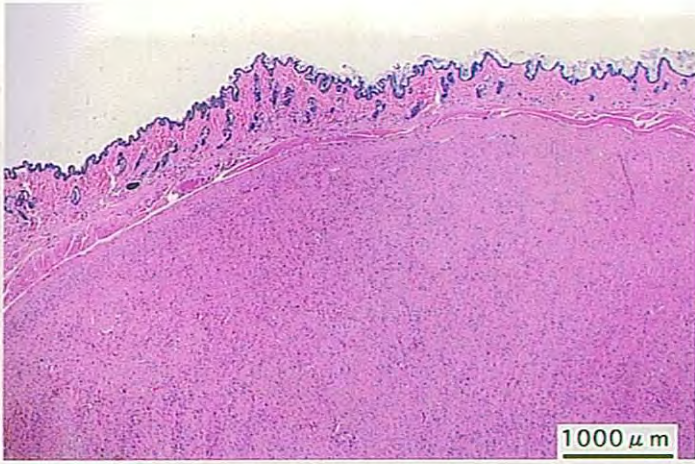
ジクロロメタンのラットを用いた  
吸入によるがん原性試験報告書

試験番号：0278

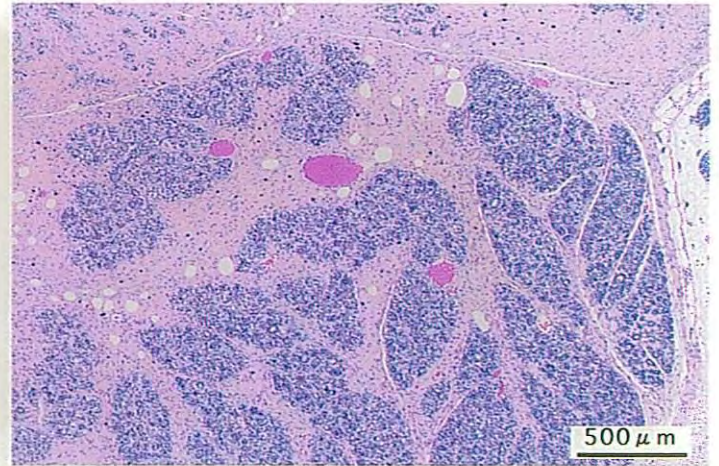
# PHOTOGRAPHS

## PHOTOGRAPHS

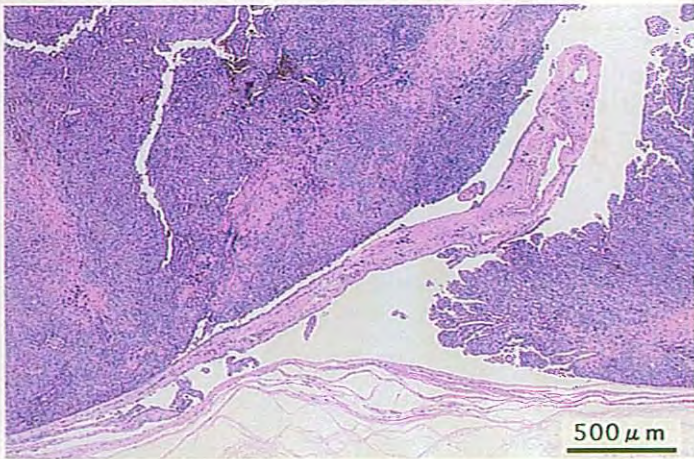
- PHOTOGRAPH 1    SUBCUTIS : FIBROMA  
                          MALE, 4000ppm, ANIMAL No. 1324 ( H&E )
- PHOTOGRAPH 2    MAMMARY GLAND : FIBROADENOMA  
                          MALE, 4000ppm, ANIMAL No. 1333 ( H&E )
- PHOTOGRAPH 3    PERITONEUM : MESOTHELIOMA  
                          MALE, 4000ppm, ANIMAL No. 1307 ( H&E )
- PHOTOGRAPH 4    LIVER : ACIDOPHILIC CELL FOCUS  
                          FEMALE, 4000ppm, ANIMAL No. 2304 ( H&E )
- PHOTOGRAPH 5    LIVER : BASOPHILIC CELL FOCUS  
                          FEMALE, 4000ppm, ANIMAL No. 2304 ( H&E )
- PHOTOGRAPH 6    LIVER : VACUOLATED CELL FOCUS  
                          FEMALE, 4000ppm, ANIMAL No. 2309 ( H&E )
- PHOTOGRAPH 7    SPLEEN : FIBROSIS  
                          MALE, 4000ppm, ANIMAL No. 1322 ( H&E )



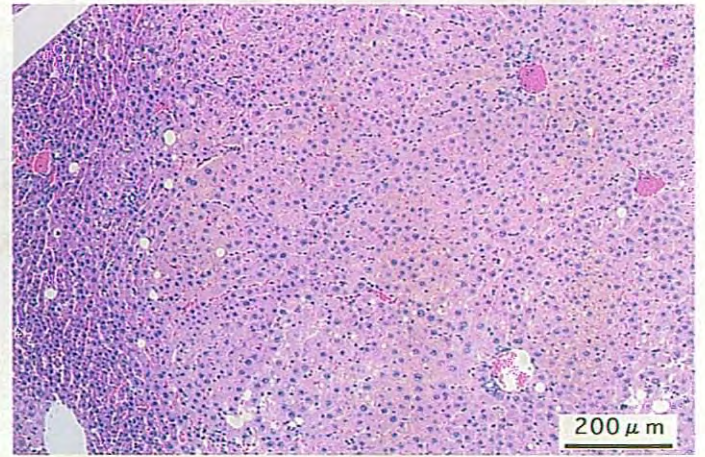
PHOTOGRAPH. 1



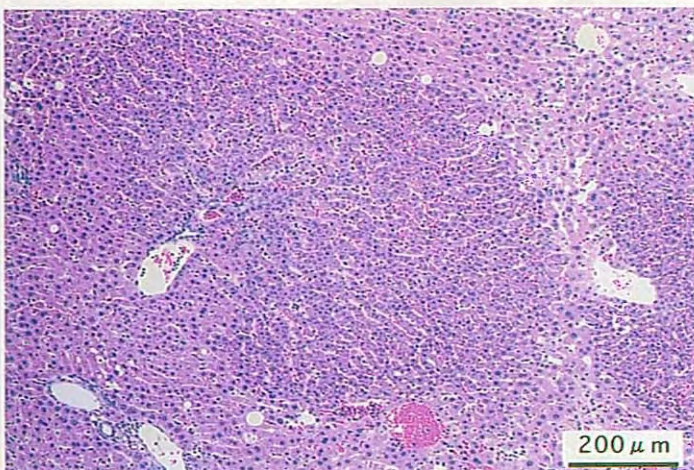
PHOTOGRAPH. 2



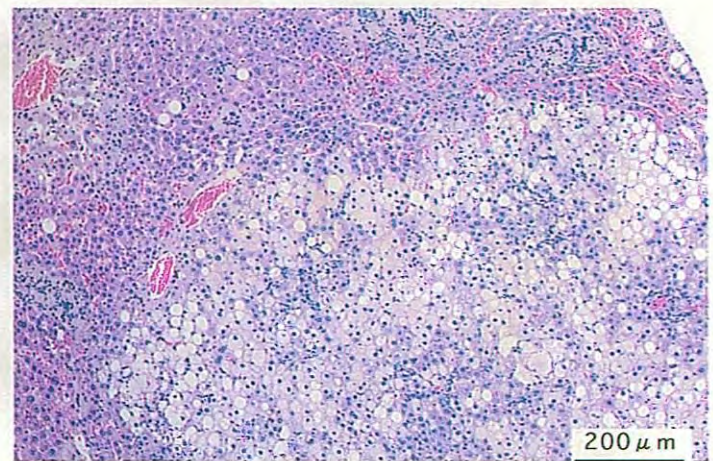
PHOTOGRAPH. 3



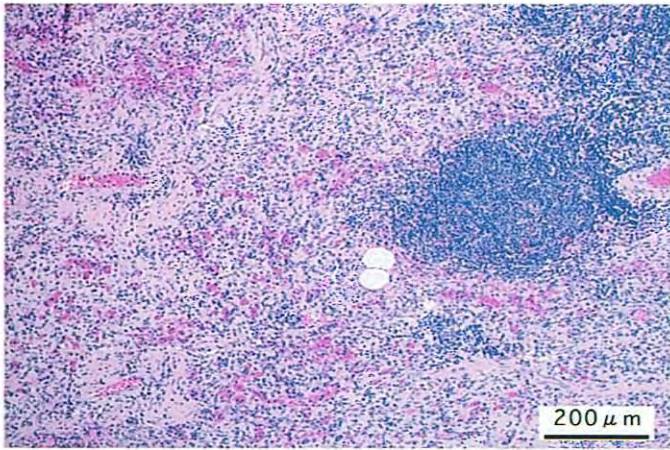
PHOTOGRAPH. 4



PHOTOGRAPH. 5



PHOTOGRAPH. 6



PHOTOGRAPH. 7