

メタリルクロライドのラットを用いた
吸入によるがん原性試験報告書

試験番号：0269

PHOTOGRAPHS

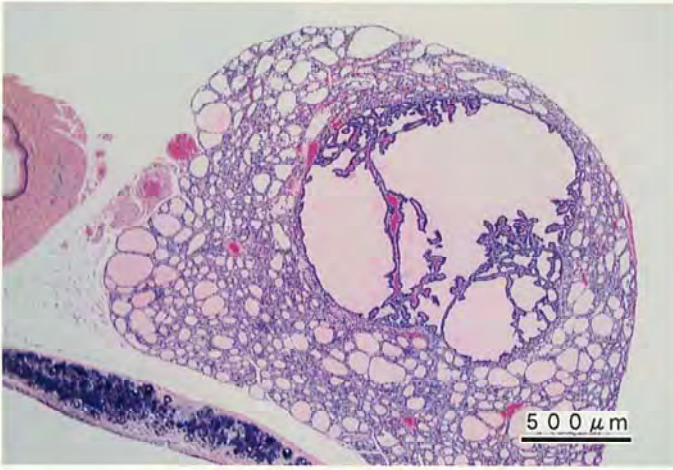
PHOTOGRAPHS

PHOTOGRAPH 1 THYROID : FOLLICULAR ADENOMA
RAT, MALE, 200ppm, ANIMAL No. 0269-1313 (H&E)

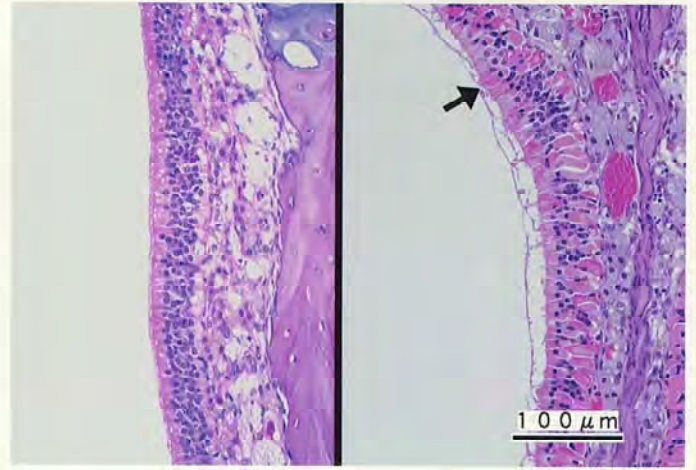
PHOTOGRAPH 2

LEFT NASAL CAVITY : NORMAL
RAT, MALE, CONTROL, ANIMAL No. 0269-1006 (H&E)

RIGHT NASAL CAVITY : EOSINOPHILIC CHANGE : OLFACTORY EPITHELIUM (↑)
RAT, MALE, 200ppm, ANIMAL No. 0269-1306 (H&E)



PHOTOGRAPH. 1



PHOTOGRAPH. 2