

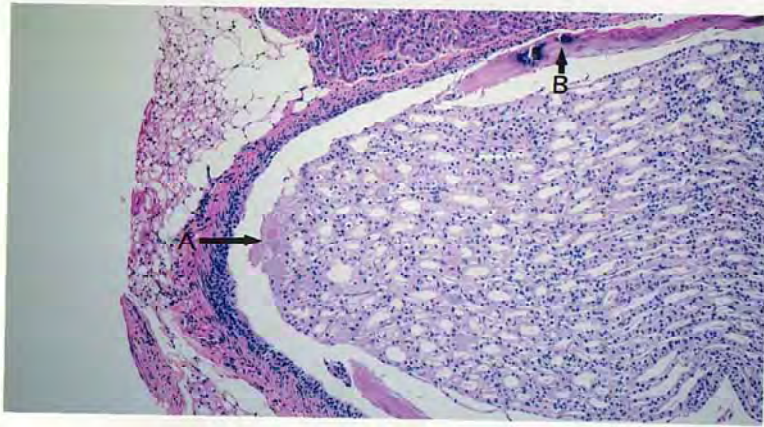グリオキサルのマウスを用いた経口投与による  
がん原性試験（混水試験）報告書

試験番号：0268

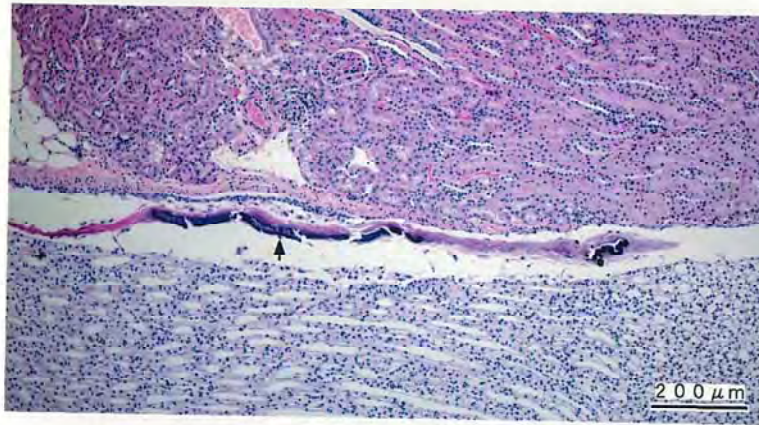
# PHOTOGRAPHS

## PHOTOGRAPHS

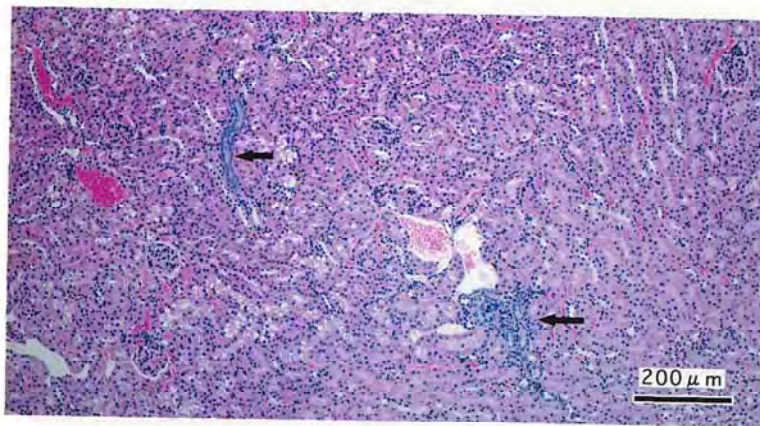
- PHOTOGRAPH 1      KIDNEY :  
                          NECROSIS : PAPANILLA (arrow A)  
                          DESQUAMATION : PELVIS (arrow B)  
                          MALE, 3000ppm, ANIMAL No. 1345 ( H&E )
- PHOTOGRAPH 2      KIDNEY : DESQUAMATION : PELVIS (arrow)  
                          MALE, 3000ppm, ANIMAL No. 1303 ( H&E )
- PHOTOGRAPH 3      KIDNEY : BASOPHYLIC CHANGE (arrow)  
                          MALE, 3000ppm, ANIMAL No. 1303 ( H&E )
- PHOTOGRAPH 4      LIVER : GRANULATION (arrow)  
                          MALE, 3000ppm, ANIMAL No. 1304 ( H&E )
- PHOTOGRAPH 5      NASAL CAVITY :  
                          EOSINOPHYLIC CHANGE : RESPIRATORY EPITHELIUM  
                          FEMALE, 6000ppm, ANIMAL No. 2316 ( H&E )
- PHOTOGRAPH 6      NASAL CAVITY :  
                          EOSINOPHYLIC CHANGE : OLFACTORY EPITHELIUM  
                          MALE, 3000ppm, ANIMAL No. 1304 ( H&E )
- PHOTOGRAPH 7      NASAL CAVITY :  
                          RESPIRATORY METAPLASIA : OLFACTORY EPITHELIUM  
                          MALE, 3000ppm, ANIMAL No. 1319 ( H&E )
- PHOTOGRAPH 8      NASAL CAVITY :  
                          RESPIRATORY METAPLASIA : GLAND (arrow)  
                          FEMALE, 6000ppm, ANIMAL No. 2327 ( H&E )



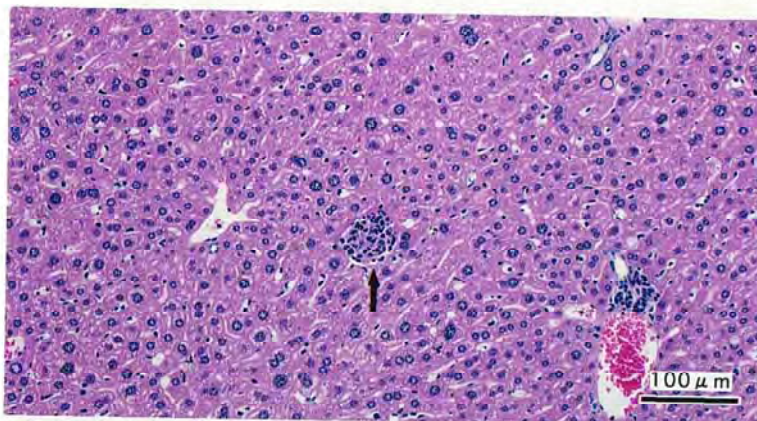
PHOTOGRAPH. 1



PHOTOGRAPH. 2

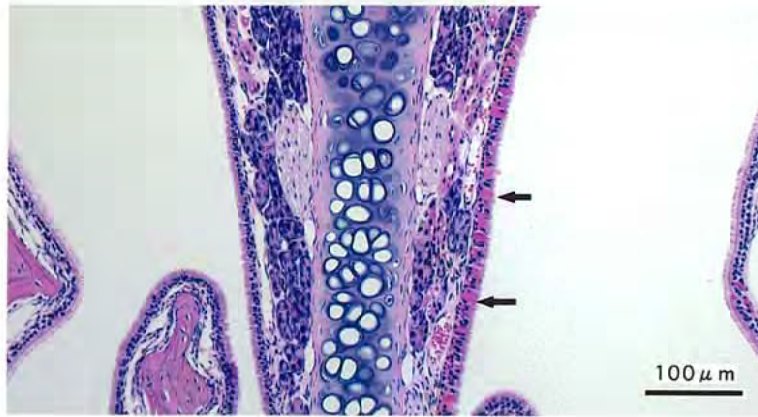


PHOTOGRAPH. 3

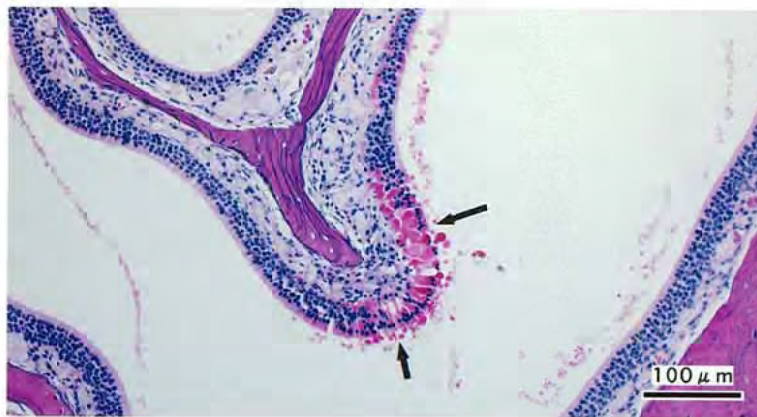


PHOTOGRAPH. 4

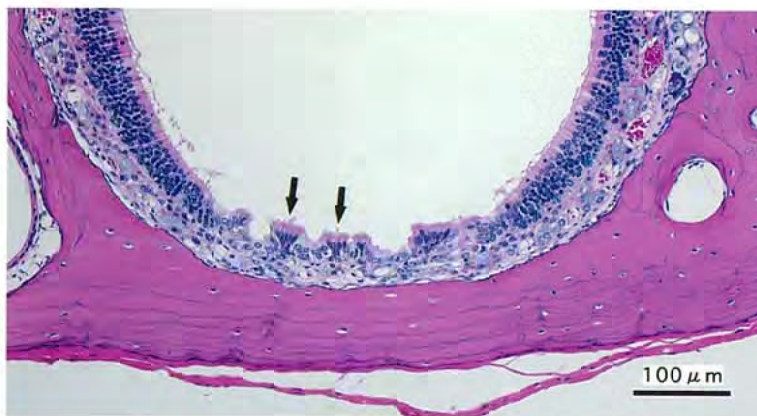



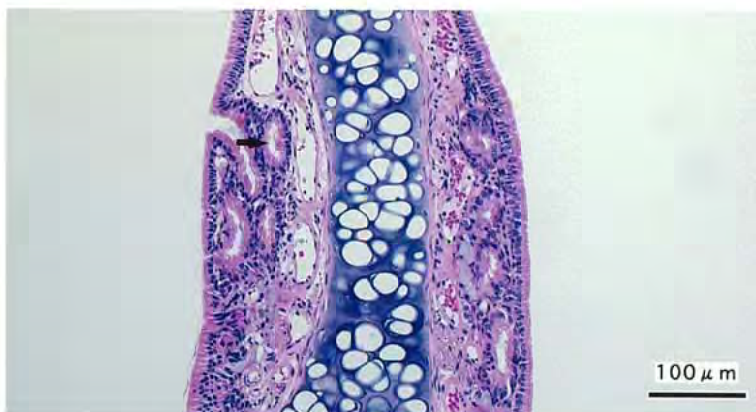
PHOTOGRAPH. 5



PHOTOGRAPH. 6



PHOTOGRAPH. 7



PHOTOGRAPH. 8