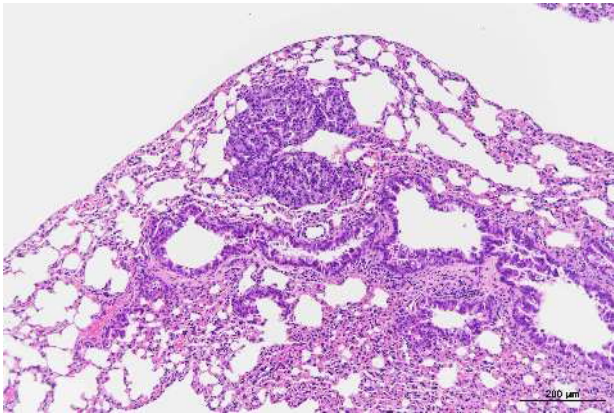


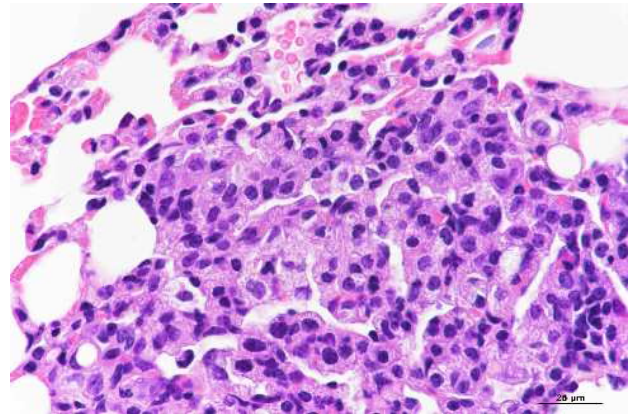
クロロエタンの rasH2 マウスを用いた
吸入による中期発がん性試験報告書

試験番号 : 0929

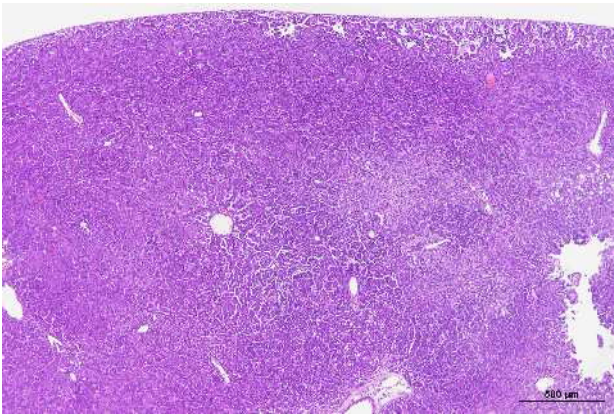
PHOTOGRAPHS



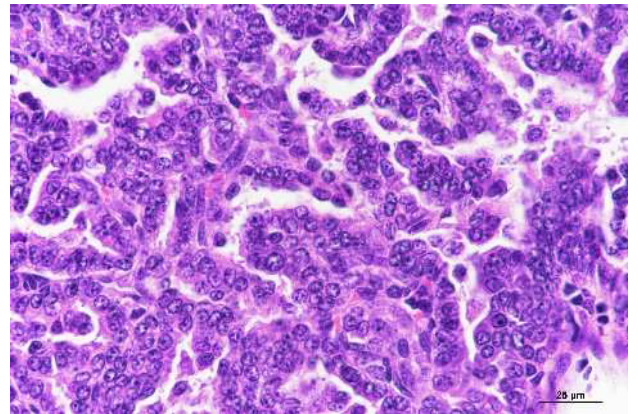Photograph 1
Lung: Bronchiolar-alveolar adenoma
Male, 15,000 ppm, Animal No. 0929-1302 (H&E)



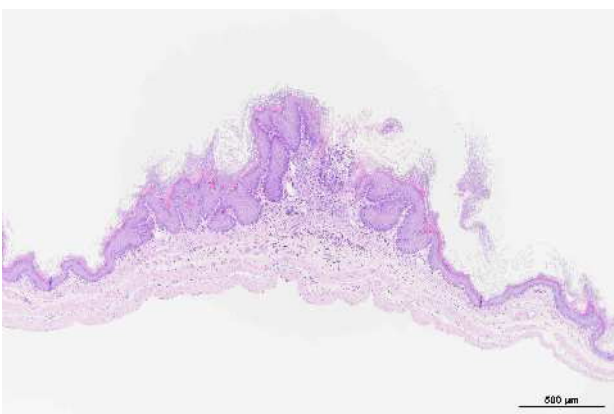
Photograph 2
High magnification of Photograph 1



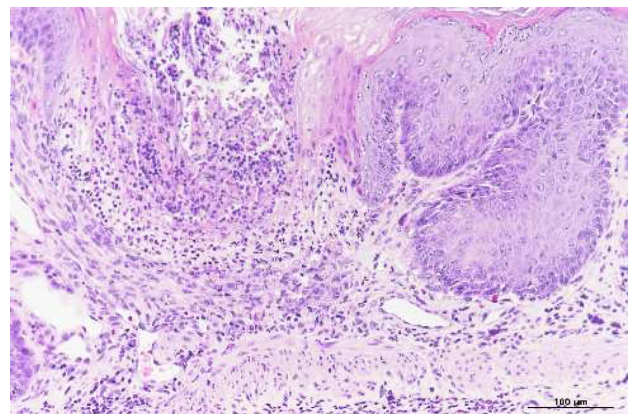
Photograph 3
Lung: Bronchiolar-alveolar carcinoma
Male, 15,000 ppm, Animal No. 0929-1315 (H&E)



Photograph 4
High magnification of Photograph 3



Photograph 5
Stomach: Hyperplasia of Forestomach
Female, 15,000 ppm, Animal No. 0929-2302 (H&E)



Photograph 6
High magnification of Photograph 5