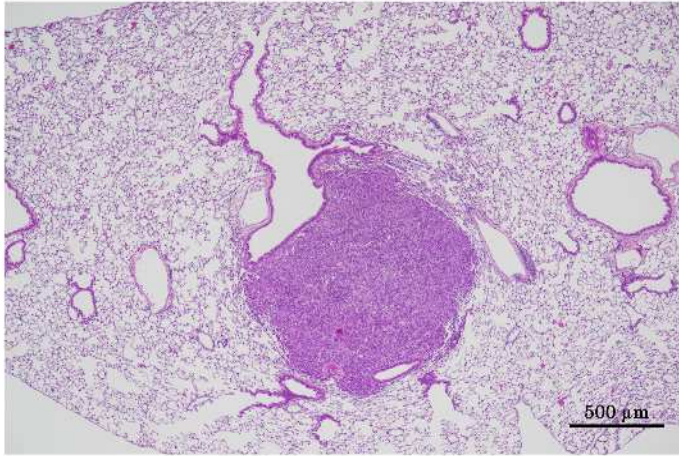


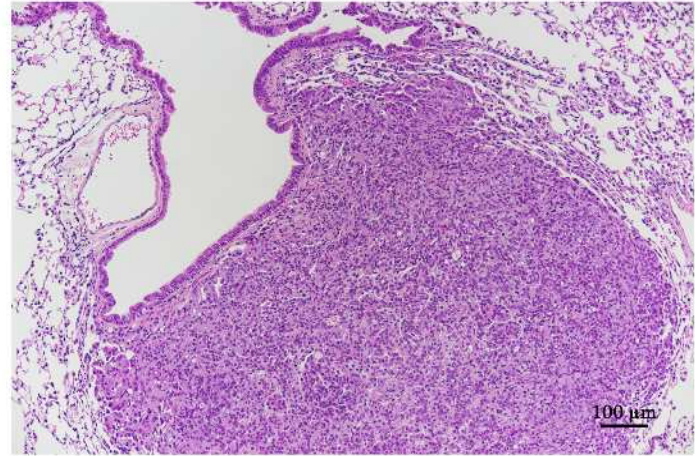
1,3,5-トリス (2,3-エポキシプロピル) ヘキサヒドロ-1,3,5-トリアジン-
2,4,6-トリオンの rasH2 マウスを用いた強制経口投与による
中期発がん性試験報告書

試験番号 : 0912, 0913

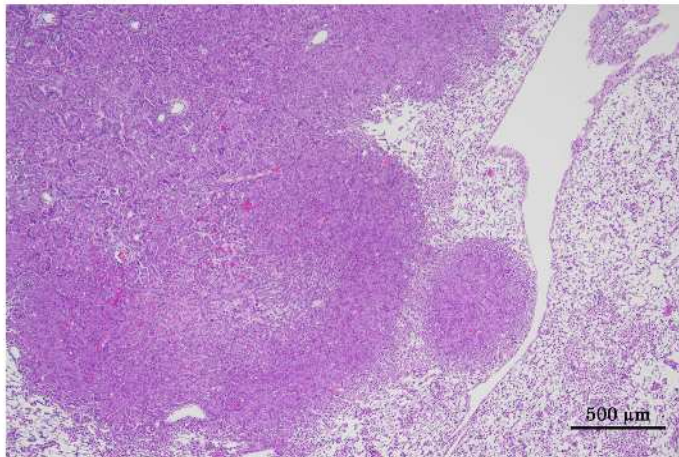
PHOTOGRAPHS



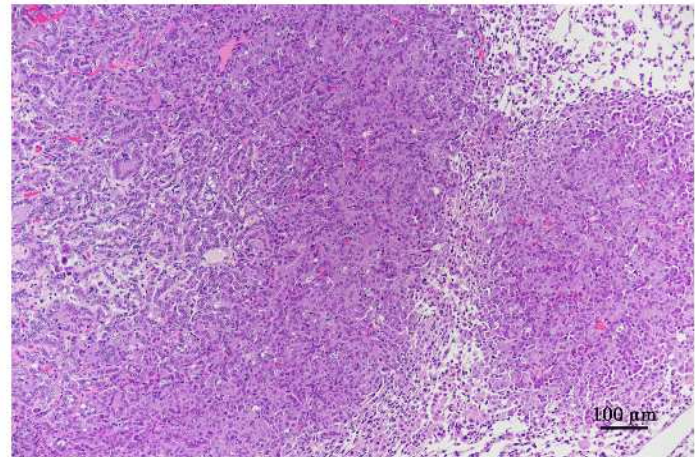
Photograph 1
Lung: Bronchiolar-alveolar adenoma
Mouse, Male, 30 mg/kg, Animal No. 0912-1310 (H&E)
Bar: 500 μm



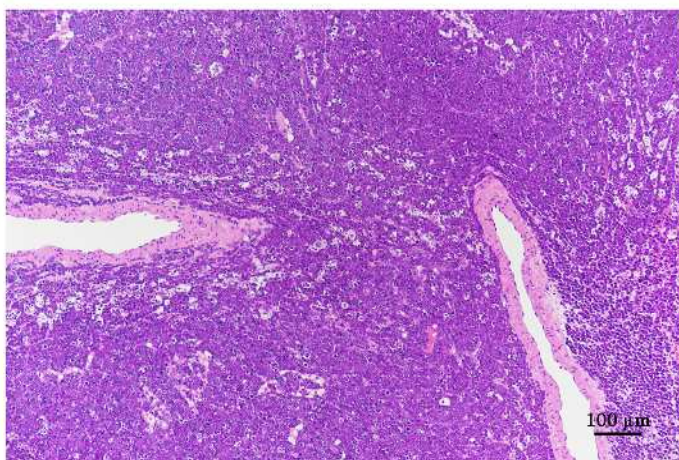
Photograph 2
High magnification of photograph 1
Bar: 100 μm



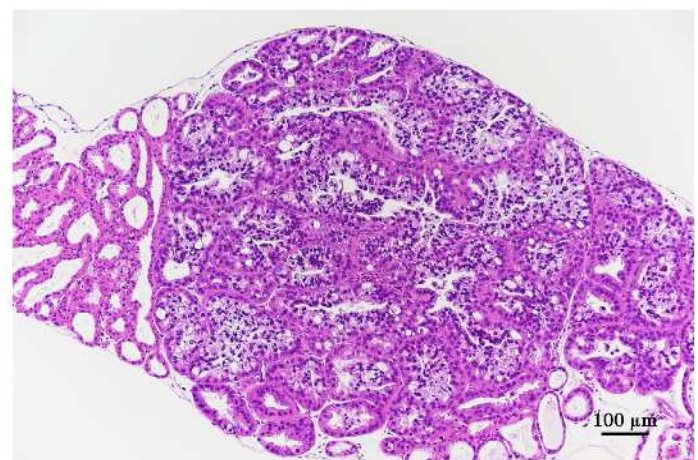
Photograph 3
Lung: Bronchiolar-alveolar carcinoma
Mouse, Male, 30 mg/kg, Animal No. 0912-1306 (H&E)
Bar: 500 μm



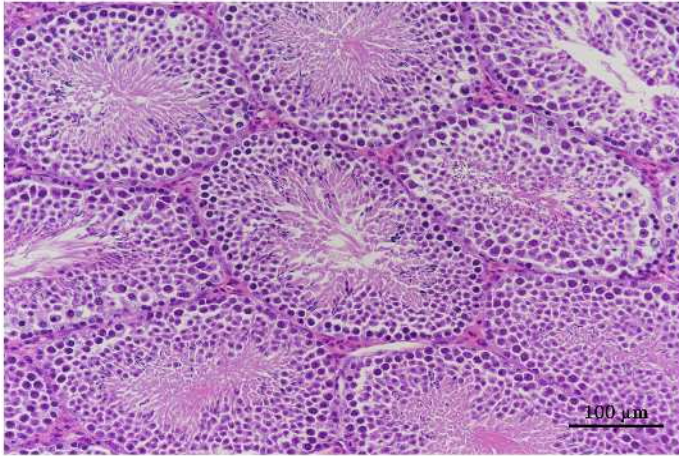
Photograph 4
High magnification of photograph 3
Bar: 100 μm



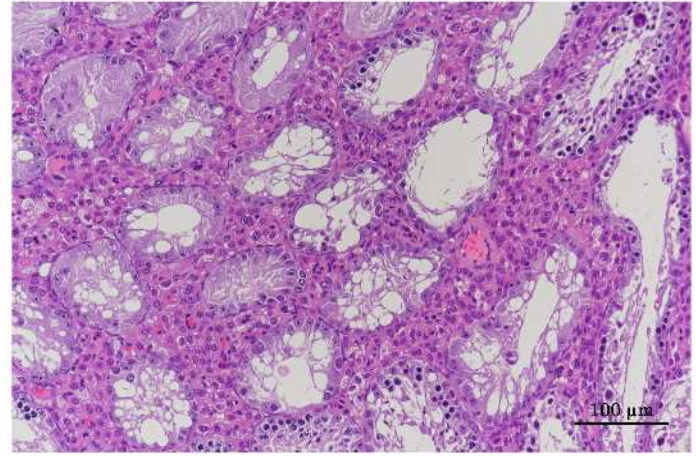
Photograph 5
Thymus: Malignant lymphoma
Mouse, Female, 30 mg/kg, Animal No. 0913-2303 (H&E)
Bar: 100 μm



Photograph 6
Harderian gland: Adenoma
Mouse, Female, 30 mg/kg, Animal No. 0913-2301 (H&E)
Bar: 100 μm



Photograph 7
Testis: Normal
Mouse, Male, 0 mg/kg, Animal No. 0912-1001 (H&E)
Bar: 100 μ m



Photograph 8
Testis: Germ cell necrosis
Mouse, Male, 30 mg/kg, Animal No. 0912-1305 (H&E)
Bar: 100 μ m