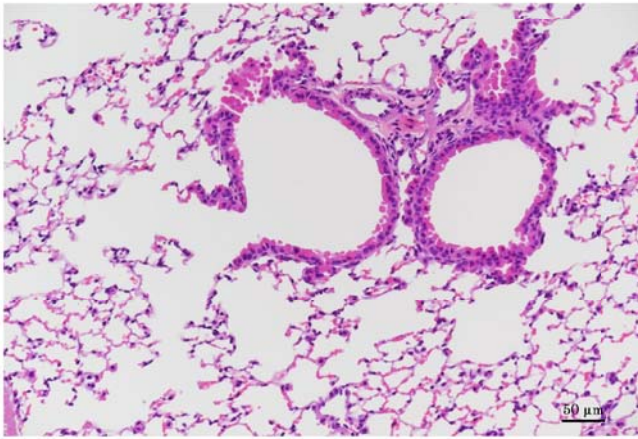


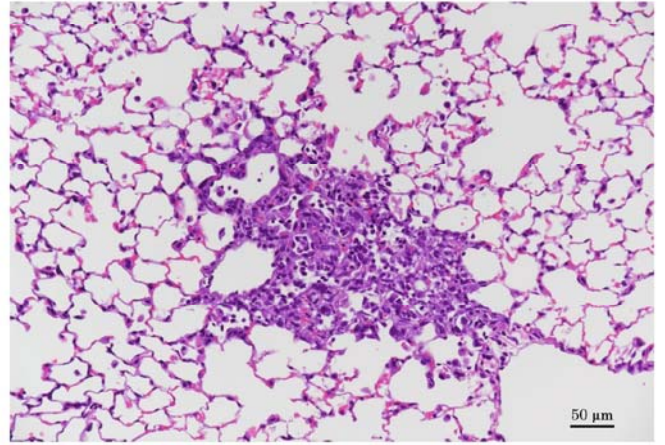
二酸化窒素の p53KO マウスを用いた吸入による
中期がん原性試験報告書

試験番号 : 0904

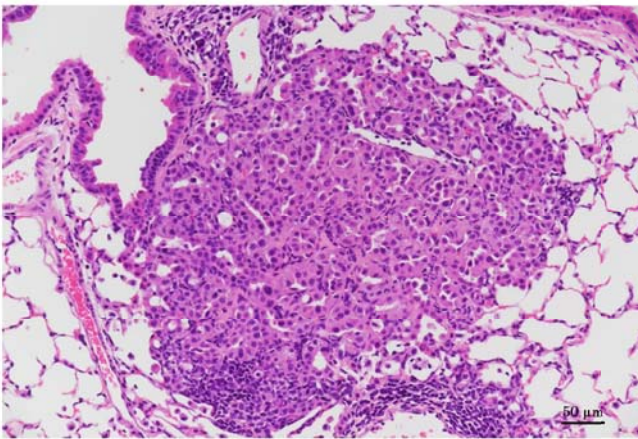
PHOTOGRAPHS



Photograph 1
Lung: Normal.
Mouse, Male, 0 ppm, Animal No. 0904-1001 (H&E)
Bar: 50 μ m



Photograph 2
Lung: Inflammatory cell infiltration focal
Mouse, Male, 40 ppm, Animal No. 0904-1319 (H&E)
Bar: 50 μ m



Photograph 3
Lung: Bronchiolar-alveolar adenoma
Mouse, Male, 40 ppm, Animal No. 0904-1311 (H&E)
Bar: 50 μ m